

## A Three-Year Experience of Medical Thoracoscopy at A Tertiary Care Center of Himalayan Region

Rakhee Sodhi<sup>1\*</sup>, Girish Sindhwani<sup>1</sup>, Shirazi Nadia<sup>2</sup>, Sanjeev Kumar<sup>1</sup>, Varuna Jethani<sup>3</sup>, Sushant Khanduri<sup>1</sup>

<sup>1</sup> Pulmonologist, Department of Pulmonary Medicine, Himalayan Institute of Medical Sciences, Swami Ram Nagar, Dehradun

<sup>2</sup> Pathologist, Department of Pathology, Himalayan Institute of Medical Sciences, Swami Ram Nagar, Dehradun

<sup>3</sup> Resident, Department of Pulmonary Medicine, Himalayan Institute of Medical Sciences, Swami Ram Nagar, Dehradun

### ARTICLE INFO

Article type:  
Original Article

Article history:  
Received: 13 Nov 2015  
Revised: 25 Dec 2015  
Accepted: 12 Feb 2016

Keywords:  
Exudative  
Pleural Effusion  
Thoracoscopy

### ABSTRACT

**Introduction:** Medical thoracoscopy is a minimally invasive procedure for diagnosing and treating pleural diseases. Despite its proven role in diagnostic and therapeutic purposes, it is infrequently used, which could be because of cost of equipment and lack of training. We analyzed our initial 3 years record of thoracoscopy at Himalayan Institute of Medical Sciences, a tertiary care center in Himalayan region of north India.

**Materials and Methods:** This cross-sectional study was to analyze our experience of medical thoracoscopy which was started in Jan 2011 at our center. All patients who underwent thoracoscopy during the period between Jan 2011 to Dec 2013 were included in the study.

Thoracoscopy was performed for diagnosis of undiagnosed pleural effusions. Clinical, radiological, cytological & histopathological data of the patients were collected prospectively and analysed.

**Results:** The diagnostic yield for a pleuroscopic pleural biopsy in our study was 87.23% (41/47). Malignancy was diagnosed histopathologically in 70.2% (33/47) patients (both primary & metastatic pleural carcinoma) and tuberculosis in 10.6% (5/47). There was no mortality related to procedure. Only three patients had minor complications like subcutaneous emphysema which was mild and resolved by second post-procedure day. Pain at intercostal drain site was observed in some patients.

**Conclusion:** Thoracoscopy is an easy outpatient procedure and an excellent diagnostic tool for pleural effusion of uncertain etiology. It has low complication rate even in settings where the procedure is just started. It should be included in the armamentarium of tools for management of pleural effusion.

► Please cite this paper as:

Sodhi R, Sindhwani G, Nadia Sh, Kumar S, Jethani V, Khanduri S. A Three-Year Experience of Medical Thoracoscopy at A Tertiary Care Center of Himalayan Region. J Cardiothorac Med. 2016; 4(1):397-402.

### Introduction

Pleural effusion, pneumothorax, and pleural thickening are frequently encountered in pulmonary practice. Despite obvious radiographic signs of pleural abnormalities, providing a specific diagnosis can present a challenge. Computed axial tomography (CT) and ultrasound scans of the thorax, and bronchoscopy with transbronchial biopsies may be helpful in

some particular circumstances, but their diagnostic yield for pleural disease is disappointingly low (1, 2).

Percutaneous access to the pleural space is diagnostically useful and relatively simple; however, approximately 25% of pleural abnormalities remain undiagnosed after thoracentesis and/or closed pleural biopsies (3,

\*Corresponding author: Rakhee Sodhi, Department of Pulmonary Medicine Himalayan Institute of Medical Sciences, Swami Ram Nagar, Dehradun (248140). Tel: 01352471362; Email: rakhee.sodhi@gmail.com

© 2016 mums.ac.ir All rights reserved.

This is an Open Access article distributed under the terms of the Creative Commons Attribution License (<http://creativecommons.org/licenses/by/3.0>), which permits unrestricted use, distribution, and reproduction in any medium, provided the original work is properly cited.

4). In case pleural thickening is the main abnormality, computed tomography-guided Abrams needle biopsy is a reasonable first-line diagnostic procedure (5).

Thoracoscopy (or pleuroscopy) involves passage of an endoscope through the chest wall, which offers clinicians a "window" for direct visualization and collection of samples from the pleura (Figure 1-3) (6). Thoracoscopy is a valuable diagnostic procedure and, in some cases, can help with disease treatment (6). Given the role of thoracoscopy in management of pleural diseases, it is largely underutilized in India due to its low cost, lack of expertise etc. In the present study, we described our three-year experience of medical thoracoscopy for diagnostic and therapeutic purposes.

## Materials and Methods

Thoracoscopy was conducted on the patients during January 2011-December 2013 in Department of Pulmonary Medicine, Himalayan Institute of Medical Sciences, Dehradun, Uttarakhand, India. Thoracoscopy was performed for diagnosis of pleural effusions, which could not be detected by pleural fluid analyses using the routine biochemical, cytological, and microbiological investigations.

All patients underwent detailed clinical evaluation with history and clinical examination. All the patients underwent the routine investigations including complete blood count and renal function tests. Prothrombin time, international normalized ratio, and platelet counts were done to rule out any bleeding tendency. Written informed consent was obtained from all the patients.

### Thoracoscopy procedure

Patients were kept fasting for six hours prior to the procedure. Lateral decubitus position, with the side of pleural effusion facing upwards, was used for the procedure. Continuous monitoring of blood pressure and pulse rate was ensured during the procedure.

Thoracoscopy was conducted under conscious sedation using intravenous aliquots of Midazolam and Fentanyl along with local anesthesia (2% solution of lidocaine). Skin was cleaned with antiseptic solution and draped with a sterilized cloth. In most of the cases, mid-axillary line was used for entry of thoracoscope, but in some patients, anterior or posterior axillary line were chosen based on clinical examination and radiological findings of loculation of fluid.

A 1-2 cm skin incision was made, followed by a blunt dissection of intercostal muscles. A trocar with inner diameter of 8 mm was inserted through the chest wall followed by the insertion of the cannula through which the thoracoscope was introduced into the pleural cavity. Rigid thoracoscope by Karl Storz (model No. 1571721) was used. Pleural fluid was sucked out with suction catheter introduced through the working channel of thoracoscope.

After achieving clear visualization, the pleural cavity was thoroughly inspected starting from diaphragmatic pleura as the first guide to the position of scope (because diaphragm movement

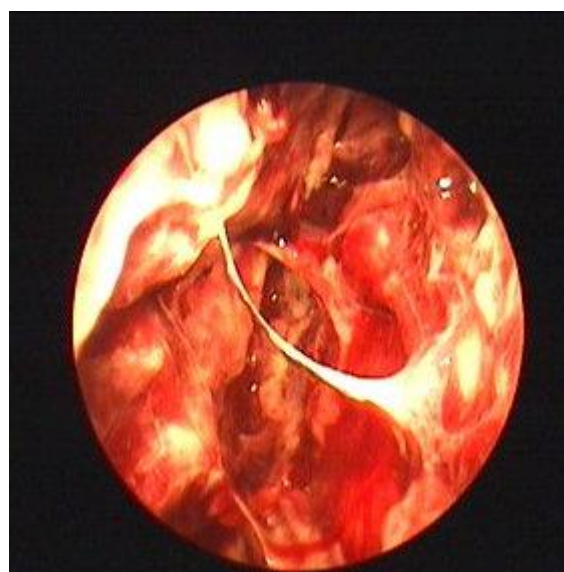


Figure 1. Thoracoscopic view of nodular pleura

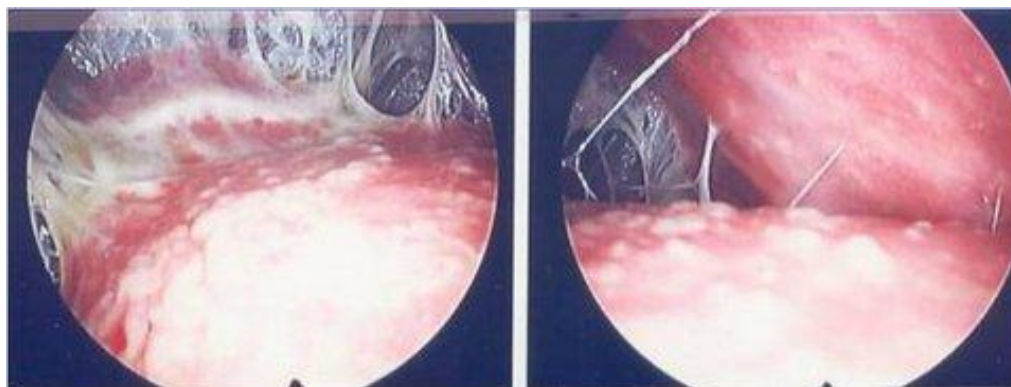
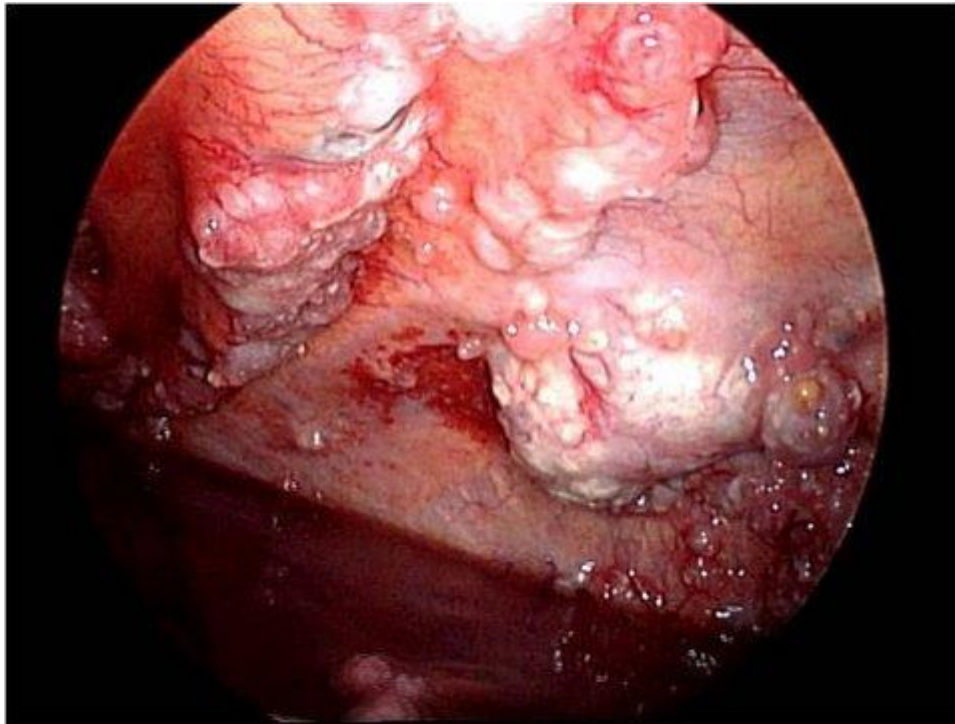


Figure 2. Thoracoscopic view of adhesions observed between both pleurae



**Figure 3.** Thoracoscopic view showing nodular pleura with abnormal rough area and hemorrhagic fluid

helps with its easy identification). Adhesions, if present, were gently broken mechanically by moving thoracoscope or biopsy forceps through them (Figure 2). Any abnormal looking area was biopsied with the help of forceps introduced via working channel (Figure 3). Following the procedure, thoracoscope and cannula were removed and under water sealed drain was inserted.

The demographic details like age, sex, smoking status, site of effusion, visual appearances on thoracoscopy, pathological diagnostic details were recorded. It was a cross-sectional study. All data were processed by SPSS software, version 11.5. It was approved by the Ethical committee of our institute Swami Rama Himalayan University.

## Results

During the above period, 47 patients (66.96% male and 34.04% female) with undiagnosed exudative pleural effusion underwent thoracoscopy. Mean age of the patients was 53.72. The baseline characteristics are shown in Table 1. Dyspnea, chest pain, and coughing were the most common symptoms in order of frequency (Table 1).

Pathologic diagnostic details are demonstrated in Table 2. The diagnostic yield for thoracoscopic pleural biopsy was 87.23%. No major complications of thoracoscopy were observed. Only three patients had minor complications such as subcutaneous emphysema, which was mild and resolved by the second post-procedure day.

Pain at intercostal drain site was observed in some patients.

## Discussion

Despite the role of medical thoracoscopy for diagnostic and therapeutic purposes, it is infrequently used, which could be due to high cost of the equipment and lack of training. Various factors can cause pleural effusion. Application of Light's criteria is helpful in differentiating between transudative and exudative effusions. Achieving a definitive diagnosis in exudative pleural effusion has always been a challenge for pulmonologists. Undiagnosed pleural effusion signifies as no definitive diagnosis is achieved by the routine investigations on pleural fluid.

**Table 1.** Baseline characteristics of the patients undergoing thoracoscopy

		No. of patients (n)	Percentage (%)
Gender	Male	35	70%
	Female	15	30%
Smoker	Yes	31	62%
	No	19	38%
Site of effusion	Right	35	
	Left	15	
Visual appearance on thoracoscopy	Adhesions	9	18%
	Nodular lesions	37	74%
	Normal pleura	4	8%

**Table 2.** Pathologic diagnostic details

Biopsy findings	No. of cases (N=47)	No. of cases	Percentage (%)
Malignancy	33 (70.2%)		
	a) Mesothelioma	10	30.30%
	b) Metastatic adenocarcinoma	10	30.30%
	c) Poorly differentiated carcinoma	7	21.21%
	d) Lymph proliferative disorders	1	3.03%
	e) Small cell	2	6.06%
	f) Round cell tumors	1	3.03%
	g) Squamous	1	3.03%
	h) Neurogenic tumor	1	3.03%
Tuberculosis	5		10.6%
Non specific inflammation	5		10.6%
Acute necrotizing inflammation	3		6.4%
No diagnosis	1		2.1%

**Table 3.** Occurrence of malignancy and other diseases in some previously published studies

Researcher's name	Total (n)	Malignancy N (%)	Tuberculosis N (%)	Non-specific Inflammation N (%)
Blanc FX.et al. (2002) [11]	149	80 (53.7) Details NA	4 (2.7)	65 (43.6)
Wang Z. et al. (2008) [13]	27	15 (51) AD 5 ME 2	6 (20)	5 (7)
Mootha V.K et al. (2011) [14]	35	17 (48.6) MM 15 ME 1 LY 1	8 (22.8)	9 (25.7)
Asmita M. et al. (2010) [15]	25	9 (45) AD 5 PD 3 ME 0	2 (10)	7 (35)
Prabhu VG. et al. (2012) [16]	68	24 (35.3) AD 15, ME 3, UC 3, LY 1, MCC1 MSC 1	16 (23.6)	22 (32.35)
Tscheikuna J. et al. (2009) [17]	86	45.35% Details NA	Not known	Not known
Aggarwal A. et al. (2014) [22]	19	13 (69) AD 10, PD 2, ME 1	3	3
Sodhi et al. (2015)*	47	33 (70.2) ME10, AD10, PD 7, LY 1, SC 2, MCC 1, MSC1, NE 1	5 (10.6)	5 (10.6)

**\* Present study**

NA-not available; AD-adenocarcinoma; ME-mesothelioma; LY-lymphoma;PD-poorly differentiated; UC-undifferentiated; MCC – metastatic clear cell carcinoma; MSC-metastatic squamous cell; SC-small cell; NE-neurogenic tumor

In the absence of thoracoscopy, pleural fluid cytology and closed pleural biopsy are the two commonly applied procedures for the diagnosis of pleural effusion (7). The diagnostic yield of cytology in malignant pleural effusion varies between 30% and 80% (8-10). In pleural effusions undiagnosed by thoracentesis, closed pleural biopsy increases the yield by about 10% and 40% in malignant and tuberculous pleural effusions, respectively(11). However, the diagnostic yield of thoracoscopy is about 93% in both malignant and tuberculous pleural effusions (11,12).

Hence, thoracoscopy is an excellent diagnostic procedure. The added advantage in thoracoscopy is the direct visualization of biopsied areas, which can increase the diagnostic yield (11). The

diagnostic yield for thoracoscopic pleural biopsy in our study was 87.23% (41/47) as we excluded patients with the diagnosis of non-specific inflammation as any confirmed diagnosis. This high yield is comparable with other studies such as Wang Z et al. (13), Mootha V.K et al. (14) and Asmita M et al. (15), where it was reported to be 93%, 74.3% and 80% respectively. Diagnostic yield with thoracoscopy was high in the study by Prabhu VG et al. (16) and Tscheikuna J et al. (17), where it approached 97% and 95.2% respectively. Comparison of some previously published studies is summarized in Table 3. The diagnostic yield with medical thoracoscopy increases even in those cases where there are no significant pleural abnormalities visible on chest CT (18).



**Table 4.** Demographics of patients diagnosed with mesothelioma

	No. of patients
Gender	
Male	7
Female	3
Smoking status	
Yes	8
No	2
Pleural appearance	
Nodular lesions	7
Normal pleura	3

Thoracoscopy can be performed either using the conventional video-assisted thoracic surgery or medical thoracoscopy. Medical thoracoscopy is performed under local anesthesia and conscious sedation while video-assisted thoracic surgery requires general anesthesia and single lung ventilation (19). For diagnostic pleural biopsy, video-assisted thoracic surgery is rarely required as medical thoracoscopy is less invasive and more cost-effective (19).

The American Thoracic Society (ATS) recommended thoracoscopy in the evaluation of undiagnosed exudative pleural effusions and in case of high clinical suspicion for malignancy (20). This would decrease delayed diagnosis and the rate of morbidity (21). Thoracoscopy saves many patients for being treated on empirical grounds.

Some of our results are inconsistent with those of other published studies. In our study, the proportion of patients diagnosed with mesothelioma was higher than the previous studies (Table 3). Mesothelioma was present in 15/33 patients (45.45% of total malignancies). It was mostly observed in non-smoking females as presented in Table 4. This is in contrast with the study by Wang Z et al. (13), where it was present in 2/15 patients; nonetheless, in a study by Asmita M et al. (15), mesothelioma was not reported. In a study by Mootha V.K et al. (14), Prabhu VG et al. (16) and Aggarwal A et al. (22), mesothelioma was present in 1/24 patients, 3/24 and 1/13 patients respectively.

This difference can be attributed to difference in the geographical (Himalayan region) and climatic atmosphere. On further evaluation of these cases of mesothelioma, it was found that all the cases belonged to the areas in and around Dehradun, capital city of Uttarakhand; however, occupational exposure to asbestos could not be found in any of the patients. Further studies should be performed to explore the reasons behind these findings.

## Conclusion

It was found that medical thoracoscopy is an easy outpatient procedure and an excellent diagnostic procedure for pleural effusion of uncertain etiology. It has low complication rate even in settings where the procedure is just started. It should be included in the armamentarium of procedures for management of pleural effusion.

## Conflict of Interest

The authors declare no conflict of interest.

## References

1. Pugatch RD, Faling LJ, Robbins AH, Snider GL. Differentiation of pleural and pulmonary lesions using computed tomography. *J Comput Assist Tomogr.* 1978; 2:601-6.
2. Feinsilver SH, Barrows AA, Braman SS. Fiberoptic bronchoscopy and pleural effusion of unknown origin. *Chest.* 1986; 90:516-9.
3. Poe RH, Israel RH, Utell MJ, Hall WJ, Greenblatt DW, Kallay MC. Sensitivity, specificity, and predictive values of closed pleural biopsy. *Arch Intern Med.* 1984; 144:325-8.
4. Ryan CJ, Rodgers RF, Unni KK, Hepper NG. The outcome of patients with pleural effusion of indeterminate cause at thoracotomy. *Mayo Clin Proc.* 1981; 56:145-9.
5. Metintas M, Ak G, Dundar E, Yildirim H, Ozkan R, Kurt E, et al. Medical thoracoscopy vs CT scan-guided Abrams pleural needle biopsy for diagnosis of patients with pleural effusions: a randomized, controlled trial. *Chest.* 2010; 137:1362-8.
6. Rodriguez-Panadero F, Janssen JP, Astoul P. Thoracoscopy: general overview and place in the diagnosis and management of pleural effusion. *Eur Respir J.* 2006; 28:409-22.
7. Emad A, Rezaian GR. Diagnostic value of closed percutaneous pleural biopsy vs pleuroscopy in suspected malignant pleural effusion or tuberculous pleurisy in a region with a high incidence of tuberculosis: a comparative, age-dependent study. *Respir Med.* 1998; 92:488-92.
8. Weissberg D, Kaufmann M, Schwecher I. Pleuroscopy in clinical evaluation and staging of lung cancer. *Poumon Coeur.* 1981; 37:241-3.
9. Canto A, Ferrer G, Romagosa V, Moyya J, Bernat R. Lung cancer and pleural effusion. Clinical significance and study of pleural metastatic locations. *Chest.* 1985; 87:649-52.
10. Stefani A, Natali P, Casali C, Morandi U. Talc poudrage versus talc slurry in the treatment of malignant pleural effusion. A prospective comparative study. *Eur J Cardiothorac Surg.* 2006; 30:827-32.
11. Blanc FX, Atassi K, Bignon J, Housset B. Diagnostic value of medical thoracoscopy in pleural disease: a 6-year retrospective study. *Chest.* 2002; 121:1677-83.
12. Rahman NM, Ali NJ, Brown G, Chapman SJ, Davies RJ, Downer NJ, et al. Local anaesthetic thoracoscopy: British Thoracic Society Pleural Disease Guideline 2010. *Thorax.* 2010; 65:ii54-60.

13. Wang Z, Tong ZH, Li HJ, Zhao TT, Li XY, Xu LL, et al. Semi-rigid thoracoscopy for undiagnosed exudative pleural effusion: a comparative study. *Chin Med J*. 2008; 121:1384-9.
14. Mootha VK, Agarwal R, Singh N, Aggarwal AN, Gupta D, Jindal SK. Medical thoracoscopy for undiagnosed pleural effusions: experience from a tertiary care hospital in north India. *Indian J Chest Dis Allied Sci*. 2011; 53:21-4.
15. Asmita M, Rajesh V, Vishwam D, Babu S, Patel V, Lakshmanan H, et al. Value of semi rigid thoracoscopy in pleural effusion. *Pulmon*. 2010; 12:43-5.
16. Prabhu VG, Narasimhan R. The role of pleuroscopy in undiagnosed exudative pleural effusion. *Lung India*. 2012; 29:128-30.
17. Tscheikuna J, Silairatana S, Sangkeaw S, Nana A. Outcome of medical thoracoscopy. *J Med Assoc Thai*. 2009; 92:S19-23.
18. Otsuka K, Otoshi T, Fujimoto D, Kawamura T, Tamai K, Takeshita J, et al. Role of medical thoracoscopy making histological diagnosis of exudative pleural effusion. *Am J Respir Crit Care Med*. 2013; 187:A4299.
19. Dhooria S, Singh N, Aggarwal AN, Gupta D, Agarwal R. A randomized trial comparing the diagnostic yield of rigid and semirigid thoracoscopy in undiagnosed pleural effusions. *Respir Care*. 2014; 59:756-64.
20. American Thoracic Society. Management of malignant pleural effusions. *Am J Respir Crit Care Med*. 2000; 162:1987-2001.
21. Beheshtirouy S, Kakaei F, Mirzaaghazadeh M. Video assisted rigid thoracoscopy in the diagnosis of unexplained exudative pleural effusion. *J Cardiovasc Thorac Res*. 2013; 5:87-90.
22. Agarwal A, Prasad R, Garg R, Verma SK, Singh A, Husain N. Medical thoracoscopy: a useful diagnostic tool for undiagnosed pleural effusion. *Indian J Chest Dis Allied Sci*. 2014; 56:217-20.