

CASE REPORT**An Isolated Mass in the Palm, Starting
Manifestation of Sarcoidosis**

Mohammad Ghorbanhoseini, MD; Hamidreza Yazdi, MD; Hossein Naseh, MD; Poopak Hafezi, MD

*Research performed at Borzooieh Hospital, Gonbad, Iran**Received: 22 Jun 2015**Accepted: 5 September 2015***Abstract**

Sarcoidosis is a systemic disease that is characterized with noncaseating granulomatous nodules which present in multiple organs specially lungs (90%). Incidence of masses due to Sarcoidosis in upper extremity is low and most cases present in association with involvement of pulmonary hilary lymph nodes. In this article we present a rare case of Sarcoidosis which presented as a single soft tissue mass in hand without osseous or pulmonary hilary lymph node involvement. Incidence of involvement of musculoskeletal system is 1-5 %, mostly it occurs in small bones in hands and feet. In most cases involvement of soft tissue in extremities is accompanied with bone lesions. Those cases of soft tissue involvement are generally coincide with pulmonary lymph nodules. To the authors' knowledge, this is the first case of Sarcoidosis that presents without spreading in bones or pulmonary hilar lymph nodes.

Keywords: Hand, Non-caseating Granulomas, Sarcoidosis**Introduction**

Sarcoidosis is a systemic idiopathic disease that is characterized with noncaseating granulomatous nodules which presents in multiple organs specially lungs (90%) (1-11). Musculoskeletal involvement is reported in 1-30% of patients (1-2). Lesions in hand has been reported in 0.2 % of patients and is rarely the first symptom (1-3, 5, 6). Most of the time disease is spread in small bones of carp and can be asymptomatic (2). If small bones of carp are affected, radiographic presentation of disease would be as a cystic-like radiolucency, lace-like lesion or would have a honey comb appearance (3).

Case Report

A 41 years old male, carpenter, right handed with chief complaint of mass in his right hand from 3 months ago was admitted in our local hospital for workup. The mass was in the first web, close to first metacarpopharyngeal joint on the palmar side and was roughly 1X1 CM in size and had slight tenderness in deep pressure. No osseous involvement, or other soft tissue mass was revealed. He reported previous trauma to his hand at work. There were no signs of inflammation. Skin perfusion was normal. Skin over the lesion was normal. The mass was mobile and firm and sensibility over the mass was normal. In the

hand X-ray bones appeared normal [Figure 1]. In the MRI a tumor was revealed the was in the muscle near skin and adjust to first metacarpopharyngeal joint in the plamar side [Figure 2]. Excisional Biopsy was done and the tissue was sent to the lab for analysis [Figure 3].

Report of pathology was: "Microscopic examination revealed fibroconnective tissue with many small naked granulomas composed of lymphocytes, epitheloid, langhans and foreign body giant cells with asteroid cytoplasmic inclusion bodies, consistent with Sarcoidosis" [Figure 4; 5].

After diagnosis of Sarcoidosis chest X-ray [Figure 6], pulmonary CT Scan [Figure 7], and Whole Body Bone Scan were done. There was no other involvement in the body and only reactive lesion in the hand was seen in the scan due to operation.

Our Rheumatologist recommended to observe the patient and didn't initiate any other treatment. After one year of follow-up with chest X-ray there is no sign of pulmonary lesion and normal scar is formed in the operation site, no signs of recurrence.

Discussion

Sarcoidosis poses a challenge in diagnosis, treatment and prognosis (1). Early diagnosis of disease can reduce potentially hazardous complications (1). Staging of disease

Corresponding Author: Mohammad Ghorbanhoseini, Research Scholar, Harvard Medical School, 67 Park Street, Brookline, MA 02446

Email: Mghorban@bidmc.harvard.edu



THE ONLINE VERSION OF THIS ARTICLE
ABJS.MUMS.AC.IR

include Bone Scan, Chest CT Scan and Chest X-ray (1). Technetium 99 Bone scan is used to survey the bones and MRI is to look after tendons and tenosynovitis (2). Surgery should be considered in treatment of systemic diseases (1). Differential diagnosis include hyperparathyroidism, Tuberculosis, Enchondroma, Thalassemia (2). Sarcoidosis arthritis is polyarticular, migratory and transient and mostly affect knee and ankle (2). Drugs used in treatment of this diseases are Corticosteroids, Methotrexate, Hydroquinone, Azathyoprin, Thalidomide and Infiximab.

Musculoskeletal involvement is reported in 1-30% of patients (1-2). Lesions in hand has been reported in 0.2 % of patients and is rarely the first symptom (1-3,5,6). Most of the time disease is spread in small bones of carp

and can be asymptomatic (2). It can spread into skin (3). If disease is present in the hand it can defile cutaneous, subcutaneous, muscle, tendon, bone and synovium tissue (3). Presenting with soft tissue involvement in hand is rare (3,4). Affected soft tissue in palm can cause flexion contracture and it can wrongfully be diagnosed and treated as trigger finger (6). It also can cause a mass that has a pressuring effect of nerves, a case of pressure on ulnar nerve and symptoms due to that pressure is reported (9).

Sarcoidosis involving limbs is a rare entity and because of that Sarcoidosis is not considered, most of the time, in differential diagnosis of masses in upper and lower limb (3,4,8-10). Also when there is a soft tissue mass in the

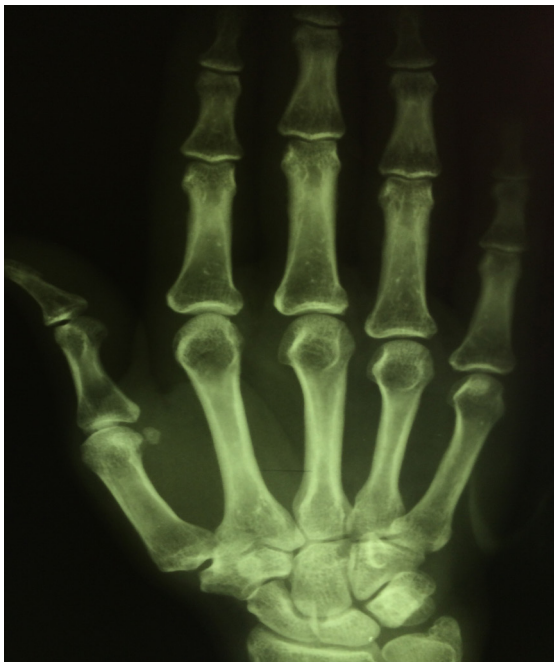

Figure 1. Hand X-ray . No Sing of mass of bone destruction.

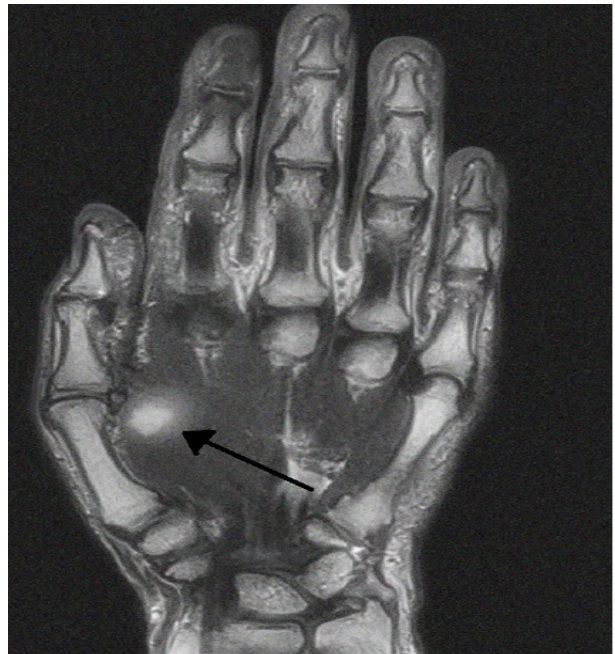


Figure 2. Hand MRI, T₁, sagittal cut. Black arrow shows a mass in the bulk of muscle.

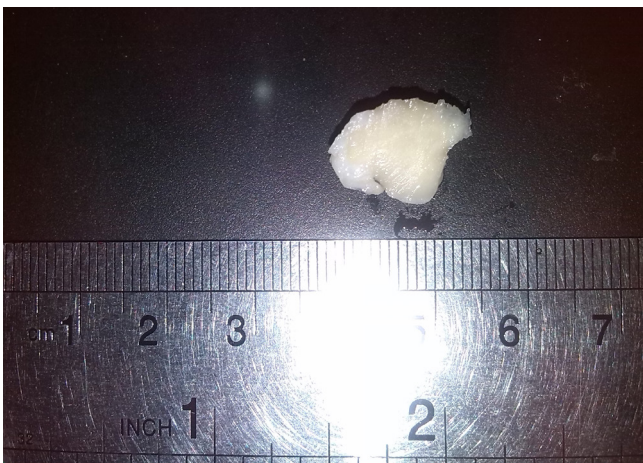

Figure 3. Gross Pathologic Specimen.

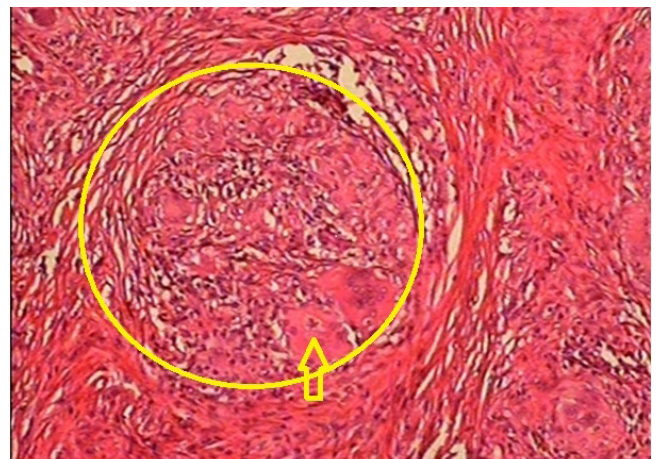


Figure 4. Hematoxylin and Eosin Stain Magnification 100X small granuloma with asteroid body (arrow) in giant cell.

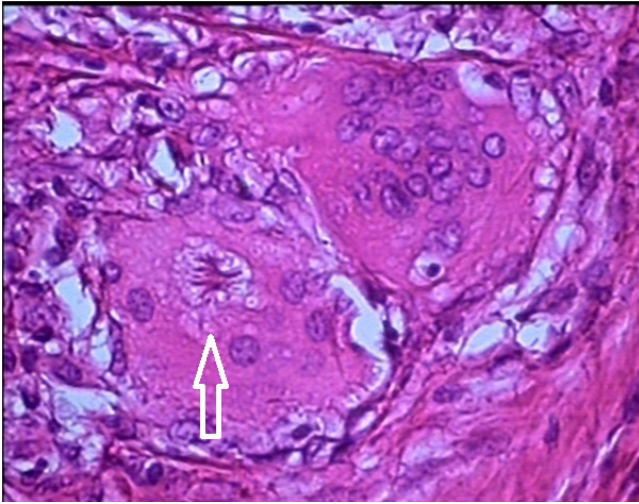


Figure 5. Hematoxylin and Eosin Stain Magnification 400X
Arrow: Asteroid body in giant cell.

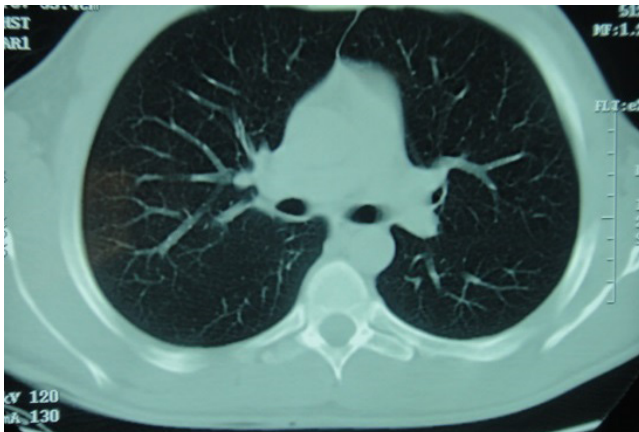

Figure 7. Chest CT Scan, Axial cut. No lesion or pulmonary Hillary lymph Node is seen.

limb, it is accompanied by prominent pulmonary hilar lymph nodes (10). To the authors' knowledge this is the first case of Sarcoidosis that presents only with a soft tissue mass in hand and has no other spreading in bones or pulmonary hilar lymph nodes.

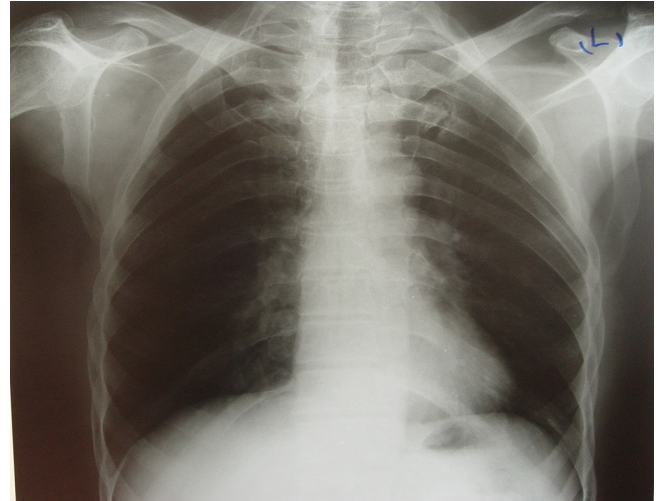


Figure 6. Chest X-ray PA.No lesion or pulmonary Hillary lymph Node is seen.

Before surgery, Sarcoidosis was not in our differential diagnosis list and after pathologic examination of sample, diagnosis was made. After surgery no drug was used and till this moment the patient has not shown any signs or symptoms of the disease in any part of his body. Although Sarcoidosis as a soft tissue mass in palm and sole is rare, it should be considered specially when the soft tissue mass does not show a specific pattern in MRI or when there are prominent pulmonary hilar lymph nodes.

Mohammad Ghorbanhoseini MD
Research Scholar, Harvard Medical School, MA, USA

Hamidreza Yazdi MD
Iran University of Medical Science, Tehran, Iran

Hossein Naseh MD
Mashhad University of Medical Sciences, Mashhad, Iran

Poopak Hafezi MD
Tehran University of Medical Sciences, Tehran, Iran

References

1. Dukworth AD, Hill AT, Beggs I, Patton JT, Salter DM, Porter DE. Sarcoidosis presenting as a proximal phalangeal bony swelling—a case and review of the literature. *Hand (N Y)*. 2010; 5(1):90–4.
2. Alemdaroglu E, Erturk A, Eroglu AG. A sarcoidosis patient with hand involvement and large pulmonary lymph nodes: results of 1-year treatment with methotrexate. *Clin Rheumatol*. 2013; 32(Suppl 1):S71-3.
3. Rivera-Sanfeliz G, Resnick D, Haghghi P. Sarcoidosis of hands. *Skeletal Radiol*. 1996; 25(8):786-8.
4. Altmann S, Schreiber J, Damert HG, Mirastschijski U, Schneider W. An isolated hand tumor as primary manifestation of sarcoidosis. *Sarcoidosis Vasc Diffuse Lung Dis*. 2011; 28(1):72-4.
5. González del Pino J, Díez Ulloa A, Lovic A, Relea MF. Sarcoidosis of the hand and wrist: a report of two cases. *J Hand Surg*. 1997; 22(5):942–5.
6. Motomiya M, Iwasaki N, Kawamura D. Finger flexion contracture due to muscular involvement of

- sarcoidosis. *Hand Surg.* 2013; 18(1):85-7.
7. Kwon B, Bindra RR, Liakos P, Gelberman RH. Extensive nodular sarcoidosis in the hand. *J Hand Surg Br.* 1997; 22(5):676-8.
 8. Pierson DJ, Willett ES. Sarcoidosis Presenting With Finger Pain. *JAMA.* 1978; 239(19):2023-4.
 9. Mattiassich G, Schubert H, Hutarew G, Wechselberger G. A rare manifestation of sarcoidosis with sensomotoric neuropathy of the ulnar nerve as the only symptom. *BMJ Case Rep.* 2012; 2012(28):1-3.
 10. Curco N, Pagerols X, Vives P. Subcutaneous sarcoidosis with dactylitis. *Clin Exp Dermatol.* 1995; 20(5):434-5.
 11. Ham SJ, Freijzer PL, Kanhai RC, van der Woude HJ. Swelling of the finger as initial manifestation of sarcoidosis. *Ned Tijdschr Geneeskd.* 2013; 157(25):A5887.