

RESEARCH ARTICLE

The Relationship Between Morphology of Lumbar Disc Herniation and MRI Changes in Adjacent Vertebral Bodies

Hamed Reyhani Kermani, MD; Ehsan Keykhosravi, MD; Masoud Mirkazemi, MD; Mohammad R Ehsaei, MD

Research performed at Department of Neurosurgery, Kerman University of Medical Sciences, Kerman, Iran

Received: 19 August 2013

Accepted: 24 December 2013

Abstract

Background: Intervertebral disc herniation has two common types, extrusion and protrusion, which may affect the adjacent vertebrae. In addition, it is associated with significant signal changes in T1 MRI (short TR/TE) and T2 MRI (long TR/TE).

Methods: The present study is a cross-sectional analytic one, in which sampling was performed retrospectively. Cases were randomly selected from the patients undergoing discectomy in our department in a one-year period. Before surgery, MRI images, T1-weighted and T2-weighted sagittal cuts were interpreted by an expert radiologist. Signal intensity of the upper and the lower adjacent vertebra and the operated herniated disc were compared with the normal discs, both in T1-weighted and T2-weighted. Changes in signal intensity were recorded in qualitative variables. Statistical analysis was then performed between two groups.

Results: In the present study, we have evaluated 170 patients undergoing lumbar disc herniation surgery, which included 97 protruded and 86 extruded discs. The patients' age ranged from 21 to 78 years old, with an average of 43.03 ± 11.4 years. Evaluating the type of discopathy with the presence of signal changes (hypo or hyper signal changes) demonstrated more signal changes in upper adjacent vertebrae in T2-weighted MRI (45.3%). However, patients with protruded discs showed less changes (30.9%). It showed that the difference was statistically significant ($P < 0.05$).

Conclusion: Extruded discs are associated with increased signal in T1-weighted MRI (short TR/TE) in the upper adjacent vertebrae. Signal changes in T2-weighted MRI (long TR/TE) in upper adjacent vertebrae are significantly more common in extruded discs, in comparison with protruded discs.

Keywords: Extrusion, Lumbar disc herniation, MRI, Protrusion, Signal change

Introduction

Lumbar disc herniation is a common condition and renders many patients who undergo surgical treatment annually. Intervertebral disk herniation remains the most common source of lumbar radiculopathy treated either with discectomy or with non-operative interventions (1, 2, 3). Although Magnetic Resonance Imaging (MRI) remains the reliable gold standard for diagnosis, the relationship between magnetic resonance imaging findings and treatment outcomes has not been well understood (4, 5, 6). Signal changes in the bone marrow adjacent to the vertebral end plate are a common finding in patients suffering from degenerative disc disease (2, 7). Unfortunately, the relationship between MRI findings and clinical courses remains controversial, with several studies show-

ing a high prevalence of disk herniations in asymptomatic subjects (8, 9). For example, Schmid *et al*, have presented 51 patients with extruded discs who undergo MRI before microsurgical resection and categorized signal changes of end-plate according to the Modic classification (Table 1) (10, 11, 12). They have studied the relationship between the classification type and the type of extruded tissue. Signal changes in vertebral end-plate showed cartilaginous extrusion (12). Other studies have described several types of signal changes which can be related to the histological findings (5, 13). However, none has studied the association between these signal changes with the type of disc herniation. We, therefore, performed this study in our department of neurosurgery.

Corresponding Author: Mohammad R Ehsaei, Shahid Kamyab Trauma Hospital, Mashhad University of Medical Sciences, Mashhad, Iran.
E-mail: ehsaeemr@mums.ac.ir



THE ONLINE VERSION OF THIS ARTICLE
ABJS.MUMS.AC.IR

Table 1. Signal changes of an end-plate according to the Modic classification

Type1	LowT1, high T2 signal, enhancement with gadolinium	Fibrovascular replacement of adjacent bone marrow
Type2	High T1 and T2 signal, without enhancement	Fatty marrow change
Type3	Low T1 and T2 signal, without enhancement	Hyperosteoisis

Table 2. The patients' duration of symptoms according to the gender

Gender	Number	Average duration of symptoms (month)	Standard deviation	Results
Male	97	14.15	20.096	<i>P</i> =0.6
Female	73	12.85	16.810	

Materials and Methods

This study is a cross-sectional analytic research, in which sampling was performed retrospectively. The cases were selected among patients who underwent surgical discectomy in Bahaonar Hospital, Kerman and in Kamyab Hospital, Mashhad, in a one-year period. The number of cases was calculated according to the 95% confidence interval, 30% prevalence (according to previous studies) and the 10% accuracy rate, based on the following formula:

$$n=(Z_2 * p (1-p)) / (d_2).$$

In our study, 183 herniated discs of 170 patients were studied (Table 2). According to the findings of surgeries, 97 cases were protruded and 86 were extruded. Duration of the disease was estimated from the beginning of a tormenting pain or a neurologic deficit, to the time of surgery. MR were taken in two distinct centers, via two 1.5-Tesla machines, with a spinal surface coil. MRI films, T1-weighted and T2-weighted sagittal cuts, which were all taken before surgery, were interpreted by an expert radiologist, who was only aware of the patients' age and gender and was blind toward the type of the herniated disc. Signal intensity of the upper and the lower adjacent vertebra and the operated herniated disc were compared with the normal discs, both in T1-weighted and T2-weighted. Changes in signal intensity are recorded as a qualitative variable. No signal change was noted as iso, increased and decreased signals were named as hyper and hypo, respectively. Statistical analysis was then performed on the data achieved from the two groups. The objective was to determine the relationship between the signal changes in bone

marrow of the adjacent vertebrae, with the type of disc herniation.

Our specific aims can be summarized as follows:

1. To determine the relationship between the duration of the symptoms with the signal changes.
2. To determine the relationship between the demographic findings with the signal changes.

Results

In this study, we have evaluated 170 patients undergoing lumbar disc herniation surgery, which showed 97 protruded and 86 extruded discs. The patients' age ranged from 21 to 78 years of age, with an average of 43.03 ± 11.4 years. Ninety-seven of patients were male (57.1%), and 73 were female (42.9%). Males' mean age was 43.86 ± 11.6 years, and females' mean age was 41.93 ± 11.3 ; this difference was not statistically significant ($P=0.2$).

The least symptomatic duration was 2 weeks and the most was 10 years, with an average symptomatic period of 13.5 months. Symptomatic duration was 14.1 ± 20.09 months in males', and was 12.8 ± 16.81 months in females, this difference was not statistically significant ($P=0.6$).

It was found that 13 patients had two levels of disc herniation, one with extrusion in both levels, four with extruded and one with protruded disc and eight with protrusion in both levels. A total number of 183 herniated discs were studied. The relationship between the type of the disc herniation and the MRI signal changes in the ad-

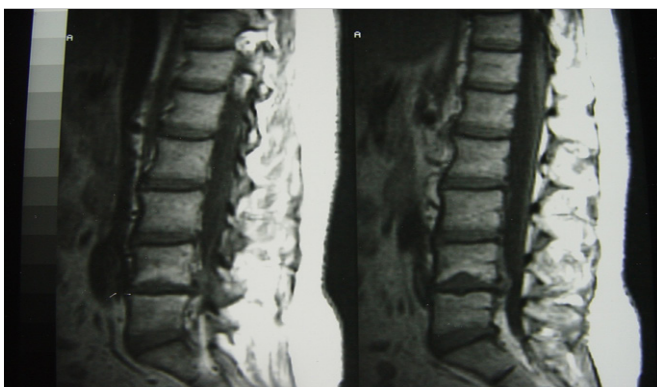


Figure 1. T1-weighted MRI shows extrusion at the level of L4-L5.

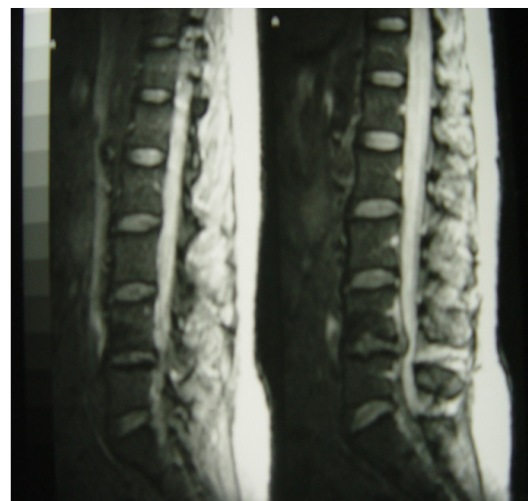


Figure 2. T2-weighted MRI shows extrusion at the level of L4-L5.

Table 3. The relationship between the type of herniation and MRI signal change in the upper and lower adjacent vertebra

Image type	MRI signal change				Results
	Protrusion		Extrusion		
	Number	Percentage	Number	Percentage	
T1 Upper vertebrae	36	37.1	43	50	$P>0.07$
T2 upper vertebrae	30	30.9	39	45.3	$P>0.05$
T1 Lower vertebrae	40	41.2	44	51.2	$P>0.1$
T2 lower vertebrae	36	37.1	43	50	$P>0.07$

adjacent upper and lower vertebrae was studied.

Results showed that in the upper adjacent vertebrae, a greater percentage of patients with extruded discs had increased signal in T1 (45.3%), however, protruded discs mostly showed no signal change or decreased signal, and a less percentage of increased signal (26.8%), this difference was statistically significant ($P<0.04$). No relationship was observed between the type of discopathy and other types of signal changes (Figure 1, 2)

Evaluation of patients with signal changes in upper vertebrae in T1-weighted MRI (either hypo or hyper), showed the relationship between the type of signal change and the type of discopathy was statistically significant ($P=0.04$) (Table3). Among extruded discs, 90.7% of discs had increased signal in T1, whereas in protruded discs 72.2% exhibited increased signals. No relationship was noted between the type of signal change and other types of discopathy.

Considering the relationship between the type of discopathy and MRI signal changes according to the gender, no statistically significant difference was observed between protruded and extruded discs in male objects. In female patients, however, this difference was statistically significant. The extruded discs showed upper adjacent vertebral signal changes in 53.1% of cases, whereas protruded discs showed in 24.4% ($P=0.02$). In lower adjacent vertebra, the percentage was 62.5% for extruded and 29.3% for protruded discs.

Studying the relationship between age and symptomatic duration with the herniation type and signal changes, analysis of variance showed no significant difference between age and symptomatic duration, whether the patient manifests signal changes or not. It can be concluded that the presence of signal changes and its relationship with the type of discopathy is not associated with age or symptomatic duration.

Discussion

A total number of 183 herniated discs (170 patients), including 86 extruded and 97 protruded discs were studied for the herniation type and MRI signal changes in upper and lower adjacent vertebra. Extruded discs showed more signal changes, hypo or hyper, in upper adjacent vertebra in comparison with protruded discs (45.3% versus 30.9%).

Evaluating the type of signal change, extruded discs showed significant increased signal in T1-weighted MRI in upper adjacent vertebra, and iso and hypo signal were less predominant comparing to protruded discs (45.3% versus 26.8%). Among patients with T1 signal changes in upper vertebrae, extruded discs showed more prominent increased signal comparing to the protruded discs (90.7%

versus 72.2%).

De Roos *et al* studied 203 disc spaces, in 41 lumbar MRI films, in order to evaluate the presentation and the intensity of adjacent vertebral signal changes in normal and degenerated discs. This study concluded that areas of increased signal in short and long TR/TE commonly occur in degenerative discs (8). In the aforementioned study, both normal and degenerated discs were studied; however, the type of disc herniation was not determined. In the present study, however, we compared extruded and protruded objects.

Modic *et al* studied the MRI films of 474 patients, and in some of cases discovered Modic type I and II, and then they studied them for histopathological criteria (14). Signal changes showed that a spectrum of marrow changes is associated with DDD (14, 15). In this study, the relationship between pathological findings with signal changes have been evaluated, however, the surgical findings are not mentioned.

Carrino *et al* studied the MRI films of 353 patients in order to evaluate the relationship between surgical outcome and modic changes (16). They concluded that surgery in patients with modic type 1 changes has better outcomes than others (p value=0.006). In 1993, Kakitsubata *et al* studied the MRI films of 709 patients in order to evaluate the signal changes of bone marrow, then divided them into types I-IV, and compared them pathologically (17). Their results showed that types I-III are commonly seen in old ages and in lower lumbar levels, and degenerative bone marrow changes include both physiologic and pathologic alterations (17). This study, like the previously mentioned one, studied the association between the signal changes and pathologic findings, not intending to investigate the type of herniated disc.

Toyone *et al* studied MRI films of 74 patients suffering DDD for end-plate and bone marrow changes and divided them into type A, with ↓SI in T1, and type B, with ↑SI in T1. Type A was associated with segmental hypermobility and back pain, whereas type B was seen in patients with stable DDD (18). This study evaluated MRI signal changes and its association with clinical manifestations, not intending to examine the pathologic and surgical findings.

To the best of knowledge, this above-mentioned study has been the only one investigating a specific type of herniation, as we did in our work therefore, it was more similar to our study. This investigation includes extruded discs only, determining the relation between the type of signal change (according to the Modic classification) with the extruded tissue. In our work, however, we selected the samples from both extruded and protruded discs and the relationship between the signal change and the herniation type was determined.

No investigation has studied the association between variables such as age, gender, and duration of symptoms with the herniation type and signal changes. We found that in male patients, no difference exists in signal changes and herniation type between extruded and protruded discs. In female patients, however, upper and lower adjacent vertebra showed more signal changes in extruded group, in comparison with the protruded (53.1 versus 24.4 in upper vertebrae, and 62.5 versus 29.3 in lower). No significant difference was observed in mean age or mean symptomatic duration among patients suffering from different types of discopathy. In conclusion, extruded lumbar discs, are associated with increased T1-weighted MRI signal (short TR/TE) in upper adjacent vertebrae. Signal changes in T2-weighted MRI (long TR/TE) in upper adjacent vertebra, are significantly more prevalent among extruded discs rather than protruded discs. Signal changes in T2 and its

association with the herniation type, showed significant differences among female patients.

Hamed Reyhani Kermani MD
Department of Neurosurgery
Kerman University of Medical Sciences, Kerman, Iran

Ehsan Keykhosravi MD
Mashhad University of Medical Sciences, Mashhad, Iran

Masoud Mirkazemi MD
Mashhad University of Medical Sciences, Mashhad, Iran

Mohammad Reza Ehsaei MD
Department of Neurosurgery
Mashhad University of Medical Sciences, Mashhad, Iran

References

- Borgesén SE, Vang PS. Herniation of the lumbar intervertebral disk in children and adolescents. *Acta Orthop Scand.* 1974;45:540-9.
- Buckwalter JA. Aging and degeneration of the human intervertebral disc. *Spine (Phila Pa 1976).* 1995;20:1307-14.
- Matsui H, Terahata N, Tsuji H, Hirano N, Naruse Y. Familial predisposition and clustering for juvenile lumbar disc herniation. *Spine (Phila Pa 1976).* 1992;17:1323-8.
- Hansson E, Hansson T. The cost-utility of lumbar disc herniation surgery. *Eur Spine J.* 2007;16:329-37.
- Weidenbaum M, Foster RJ, Best BA, Saed-Nejad E, Nickoloff E, Newhouse J, et al. Correlating magnetic resonance imaging with the biochemical content of the normal human intervertebral disc. *J Orthop Res.* 1992;10:552-61.
- Hakelius A. Prognosis in sciatica. A clinical follow-up of surgical and non-surgical treatment. *Acta Orthop Scand Suppl.* 1970;129:1-76.
- Higuchi M, Kaneda K, Abe K. Postnatal histogenesis of the cartilage plate of the spinal column: electron microscopic observations. *Spine (Phila Pa 1976).* 1982;7:89-96.
- de Roos A, Kressel H, Spritzer C, Dalinka M. MR imaging of marrow changes adjacent to end plates in degenerative lumbar disk disease. *AJR Am J Roentgenol.* 1987;149:531-4.
- Atlas SJ, Keller RB, Chang Y, Deyo RA, Singer DE. Surgical and nonsurgical management of sciatica secondary to a lumbar disc herniation: five-year outcomes from the Maine Lumbar Spine Study. *Spine (Phila Pa 1976).* 2001;26:1179-87.
- Lee JM, Nam KH, Lee IS, Park SK, Choi BK, Han IH. Modic degenerative marrow changes in the thoracic spine: a single center experience. *J Korean Neurosurg Soc.* 2013;54:34-7.
- Hutton MJF, Bayer JHMDF, Powell JMF. Modic vertebral body changes: The natural history as assessed by consecutive magnetic resonance imaging. *Spine.* 2011;36:2304-7.
- Schmid G, Witteler A, Willburger R, Kuhnen C, Jergas M, Koester O. Lumbar Disk Herniation: Correlation of histologic findings with marrow signal intensity changes in vertebral endplates at MR imaging. *Radiology.* 2004;231:352-8.
- Deyo RA, Loeser JD, Bigos SJ. Herniated lumbar intervertebral disk. *Ann Intern Med.* 1990;112:598-603.
- Modic MT, Masaryk T, Boumpfrey F, Goormastic M, Bell G. Lumbar herniated disk disease and canal stenosis: prospective evaluation by surface coil MR, CT, and myelography. *AJR Am J Roentgenol.* 1986;147:757-65.
- Modic MT, Ross JS. Magnetic resonance imaging in the evaluation of low back pain. *Orthop Clin North Am.* 1991;22:283-301.
- Carrino JA, Morrison WB, Parker L, Schweitzer ME, Levin DC, Sunshine JH. Spinal injection procedures: volume, provider distribution, and reimbursement in the U.S. medicare population from 1993 to 1999. *Radiology.* 2002;225:723-9.
- Kakitsubata Y, Nabeshima K, Kakitsubata S, Watanabe K. Evaluation of lumbar vertebral bone marrow changes with MR imaging. *Nihon Igaku Hoshasen Gakkai Zasshi.* 1993;53:1267-82.
- Toyone T, Takahashi K, Kitahara H, Yamagata M, Murakami M, Moriya H. Vertebral bone-marrow changes in degenerative lumbar disc disease. An MRI study of 74 patients with low back pain. *J Bone Joint Surg Br.* 1994;76:757-64.