

## An isolated burkitt's lymphoma of the chest wall: First case reported in a malagasy child

Narindra Narindra Mihaja Razafimanjato<sup>\*1</sup>, Rindra Andrianina Ralaivao<sup>2</sup>, Guillaume Odilon Tsiambanizafy<sup>1</sup>, Hanitrana Jean Louis Rakotovao<sup>1</sup>, Francis Allen Hunald<sup>3</sup>

<sup>1</sup>Thoracic surgeon, Teaching Hospital of Joseph Ravoahangy Andrianavalona, Department of Surgery & Division of Thoracic Surgery. Faculty of Medicine, University of Antananarivo. Madagascar.

<sup>2</sup>Pathologist, Teaching Hospital of Joseph Ravoahangy Andrianavalona, Department of Anatomical Pathology, Faculty of Medicine, University of Antananarivo. Madagascar.

<sup>3</sup>Paediatric surgeon, Teaching Hospital of Joseph Ravoahangy Andrianavalona, Department of Surgery & Division of Paediatric Surgery, Faculty of Medicine, University of Antananarivo. Madagascar.

### ARTICLE INFO

Article type:  
Case report

Article history:  
Received: 02 March 2020  
Revised: 19 March 2020  
Accepted: 13 June 2020

Keywords:  
Burkitt Lymphoma  
B Cell  
Chest Wall Tumour

### ABSTRACT

Primary Burkitt lymphomas of the chest wall are relatively rare in occurrence. The authors describe a first case report in Malagasy child. It presents as an isolated soft-tissue mass on the chest wall with a sudden installation of paraplegia in an 8-year-old girl. Our patient was treated with aggressive chemotherapy regimen with complete remission on 2 years of follow-up.

► Please cite this paper as: Razafimanjato, N., Ralaivao, R., Tsiambanizafy, G., Rakotovao, H., Hunald, F. An Isolated Burkitt's Lymphoma Of The Chest Wall: First Case Reported In A Malagasy Child. J Cardiothorac Med. 2020; 8(4):723-726

### Introduction

Burkitt's lymphoma (BL) is a non-Hodgkin's malignant lymphoma (NHML) described in 1957 by Denis Parsons Burkitt in African child, Kampala, Uganda [1]. Thoracic

manifestation of Burkitt's lymphomas is rare, particularly if it's located on the wall [2]. This paper describes an unusual case of isolated primary Burkitt lymphoma that presented as a mass rapidly growing, originating from the

\*Corresponding author: Narindra Narindra Mihaja, Teaching Hospital of Joseph Ravoahangy Andrianavalona, Department of Surgery & Division of Thoracic Surgery. Faculty of Medicine, University of Antananarivo. Madagascar. Tel & Fax: +261349368720. E-mail: [razafesteban@yahoo.fr](mailto:razafesteban@yahoo.fr)

© 2016 mums.ac.ir All rights reserved.

This is an Open Access article distributed under the terms of the Creative Commons Attribution License (<http://creativecommons.org/licenses/by/3.0>), which permits unrestricted use, distribution, and reproduction in any medium, provided the original work is properly cited.

chest wall muscles and causing hip pain in immunocompetent children with no history of infection and responding spectacularly to chemotherapy.

### Case presentation

An 8-year-old girl was seen in consultation for a posterolateral swelling of the right hemithorax and a pain in the hip mostly nocturnal that had been evolving for three weeks, only calmed by the anteflexion position. She had no history of hemopathy or cancer in the family. Her vaccinations were up to date. The child had no fever or breathlessness. Swelling was located at the right of the lower chest wall. It was non-inflammatory and non-painful. The lymph node areas were free of adenopathy. Our young patient had presented a sudden motor deficit of the lower limbs one week following her medical consultation. Symptomatology responded positively to corticosteroid treatment. Complete blood count, C-reactive protein and blood glucose were normal. There was no anaemia or hyperleukocytosis. Kidney function tests were clean. Vanilylmandelic acid, homovanillic acid and urinary dopamine was normal. Lactate dehydrogenase was elevated to 890 IU. Uricemia was 95 mg/L. Tuberculosis testing and HIV serology were negative. Direct examination and cultures of sputum failed to grow any infectious agents while Ziehl-Neelsen stain for acid-fast bacilli and mycobacterium tuberculosis were negative. Chest X-ray revealed a mass on the lateral side of the right thoracic wall. The enhanced CT scan of the chest revealed a right parietal mass, with a poorly limited para-vertebral and pleuropulmonary extension, pushing the right lung though not invading it (Figure 1). A dorsal MRI without Gadolinium injection was performed and with T1 and T2 weighting, the tissue mass that sized nearly 100x100x80mm appeared with a homogenous iso signal. It involved the right lower thoracic wall, the pleural cavity and extended into the medullary canal, encompassing the roots at T6 to T9. It invaded the right diaphragm and pushed down the liver (Figure 2). After injection of gadolinium, the mass showed an elevation of the peripheral part. A non-contributory fine needle aspiration biopsy was undertaken. A surgical excision was performed for biopsy. The result of the

histopathological examination suggested Burkitt's lymphoma (Figure 3). The child was

Referred to pediatric oncology where she received chemotherapy (Three cycles of CODOX-M: cyclophosphamide, vincristine, doxorubicin, high-dose methotrexate, and intrathecal therapy) with better disease outcomes on MRI control (Figure 4). A complete remission was noticed after 2 years' follow-up.

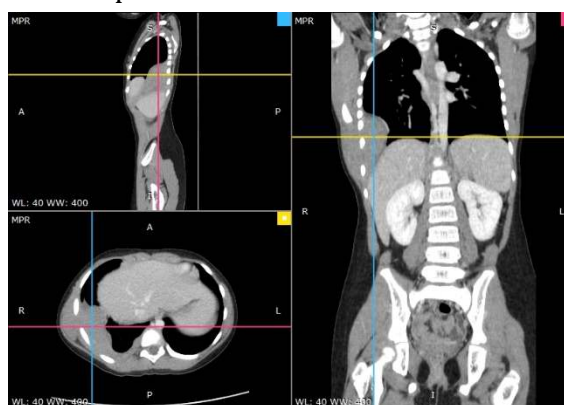

Figure 1: Image from initial CT scan showing

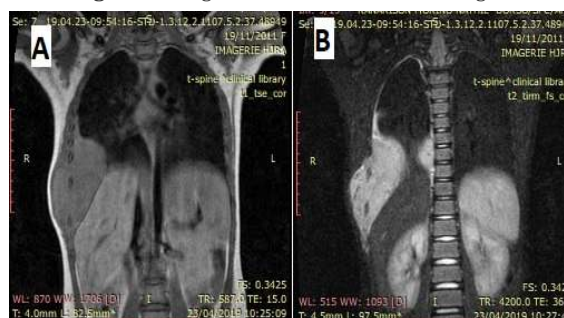


Figure 2: MRI revealed invasion of the anterior spinal cord and the intramedullary tumoral extension is located at T6 and T9 level.

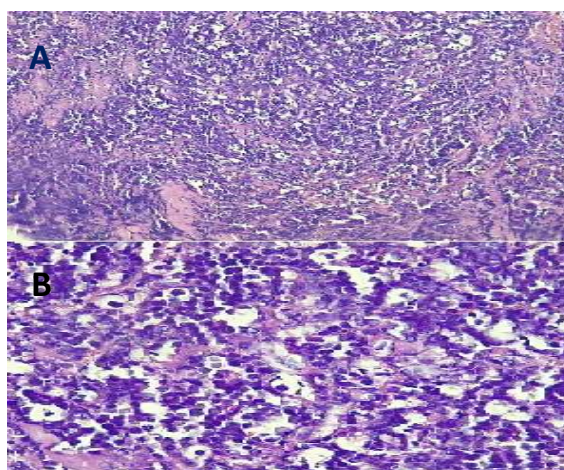


Figure 3: (A-B) Slides revealed lymphocytes with deeply basophilic cytoplasm in a "starry-sky" pattern characteristic of Burkitt lymphoma.

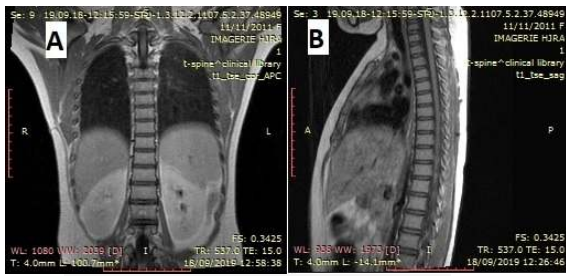


Figure 4: Image from post-treatment MRI.

## Discussion

Burkitt lymphoma (BL) is a highly aggressive B-cell lymphoma, which accounts for approximately 30 to 40 % of Non-Hodgkin Lymphoma (NHL) in children [3]. They are malignant neoplasms of lymphocytic lineage [4]. Extranodal lymphoma is the most common type of cancer among children and its localization is often in the gastrointestinal tract [4]. The primary involvement of the chest wall by a lymphoma, observed in our clinical case is indeed a rare occurrence. Nilgun Yaris et al reported one similar case [4]. Clinical manifestations vary from the localization of the tumour. The discovery of the cancer occurs mostly either through a mass, whether it is symptomatic or not, or through imaging in clinical emergency [3-5]. In our observation, thoracic wall mass has been noticed while the patient felt a right basithoracic pain for a few weeks [2]. This is an isolated and sporadic involvement of the chest wall of the BL in a child with no prior medical history of Epstein Barr virus infection. The symptoms were focused on a chest wall mass, a hip pain and a lower limb paralysis. The origin of the hip pain is debatable in this clinical case, as the invasion of the anterior spinal cord and the intramedullary tumoral extension are located at T6 and T9 level on MRI. A referred hip pain cannot be ruled out. According to Ouaglia et al, chest X-ray is not enough to describe completely chest soft tissue tumor as an extranodal lymphoma [6]. However, this is the first imaging requested for a chest wall anomaly that can give an accurate information to the clinician about the bone or soft tissue involvement which can lead to a suspicion of a parietal tumefaction or soft tissue swelling. Computed tomography gives a more accurate assessment of the tumour morphology, its specificities and localization although its assessment is lower compared to

that of a Medical Resonance Imaging (MRI) when the medullary extent needs to be visualized as in our present case [7]. Positron Emission Tomography CT examination (PET scan) usually shows a high uptake of fluoro-deoxy-glucose throughout the mass. It has been used for both functional and anatomic assessment during the tumour-staging process and the follow-up period after treatment [8-10]. This exam has not been carried out since the technical platform is not available in our centre. This situation can misrepresent the staging process, lowering the BL correct staging in our patient. The diagnosis of a BL must be established by either a histopathological examination of a tissue biopsy, or a surgical excision. One of the most common ways to confirm diagnosis is to have recourse to a fine needle biopsy (Tru-cut biopsy). The major benefits of this approach consist of a high diagnostic value combined with a low incidence of morbidity. We observed that excisional biopsy shall be carried out in case the Tru-Cut biopsy results are unsuccessful or inconclusive [11]. Burkitt lymphomas and "Burkitt type" lymphomas are similar and are both highly aggressive. However, the prognosis is generally favourable after a chemotherapy treatment [8]. In literature, similar to our case, CODOX-M protocol represents a significant advance for the management of Burkitt's lymphoma with favourable response [12].

## Conclusion

Burkitt's lymphoma, which grows mainly from soft tissue, is a very rare cancer. As it is isolated, the symptomatology is limited to parietal swelling associated with neuromuscular symptom. The role of surgery in the management of BL is to establish the histopathological diagnosis through a tissue analysis following a biopsy sampling. Combined with a multi-modality treatment, the definitive and most appropriate treatment must be established by the paediatric oncologists, moreover impelled by a multidisciplinary follow-up and evaluation.

## Source of Funding

No source of funding.

## Conflict Of Interest Statement

None of the authors has any conflicts of interest or any financial ties to disclose. Written informed consent was taken from the



patient for publication of this case report and figures.

### Ethical Approval

The authors declare that the involved patient gave his informed consent for participation in research. The study was done according to the declaration of Helsinki.

### Acknowledgments

We thank the Radiological Department (Director: Prof. Ahmad A) for providing the CT scan and MRI results for their useful suggestions that greatly improved the manuscript.

### References

1. Uzer F, Dertsiz L, Cilli A. Burkitt's Lymphoma Presenting as Endobronchial Lesion. *Clin Med Rev Case Rep*. 2017;4:178.
2. Lu R. Primary burkitt lymphoma of the chest wall. *Case reports in hematology*. 2012;2012.
3. Kalisz K, Alessandrino F, Beck R, Smith D, Kikano E, Ramaiya NH, Tirumani SH. An update on Burkitt lymphoma: a review of pathogenesis and multimodality imaging assessment of disease presentation, treatment response, and recurrence. *Insights into imaging*. 2019 Dec 1;10(1):56.
4. Yaris N, Cakir M, Ahmetoglu A, Ersoz S. Primary Burkitt's lymphoma only involving the chest wall at relapse in a child. *Leukemia & lymphoma*. 2004 Apr 1;45(4):837-9.
5. Brousse N, Vasiliu V, Michon J, Canioni D. Lymphomes non hodgkiniens de l'enfant. *In Annales de Pathologie* 2004 Dec 1 (Vol. 24, No. 6, pp. 574-586). Elsevier Masson.
6. La Quaglia MP. Chest wall tumors in childhood and adolescence. *In Seminars in pediatric surgery* 2008 Aug 1 (Vol. 17, No. 3, pp. 173-180). WB Saunders.
7. Derinkuyu BE, Boyunağa Ö, Öztunalı Ç, Tekkeşin F, Damar Ç, Alımlı AG, Okur A. Imaging features of Burkitt lymphoma in pediatric patients. *Diagnostic and Interventional Radiology*. 2016 Jan;22(1):95.
8. Bailly C, Eugène T, Couec ML, Strullu M, Frampas E, Champion L, Kraeber-Bodéré F, Bodet-Milin C. Prognostic value and clinical impact of 18FDG-PET in the management of children with Burkitt lymphoma after induction chemotherapy. *Frontiers in Medicine*. 2014 Dec 16;1:54.
9. Uslu L, Donig J, Link M, Rosenberg J, Quon A, Daldrup-Link HE. Value of 18F-FDG.
10. PET and PET/CT for evaluation of pediatric malignancies. *Journal of Nuclear Medicine*. 2015 Feb 1;56(2):274-86.
11. Gopal S, Gross TG. How I treat Burkitt lymphoma in children, adolescents, and young adults in sub-Saharan Africa. *Blood*. 2018 Jul 19;132(3):254-63.
12. Stelzer P, Gay Jr WA. Tumors of the chest wall. *The Surgical clinics of North America*. 1980 Aug 1;60(4):779-91.
13. Braman SS, Mark EJ. Case 26-1991: An 81-Year-Old Man with Collapse of the Right Upper and Middle Lobes. *New England Journal of Medicine*. 1991 Jun 27;324(26):1876-84.