

Protective effects of vitamin D on ischemia-reperfusion injury of the ovary in a rat model

Vehbi Yavuz Tokgoz ^{1*}, Mehmet Sipahi ¹, Ozlem Keskin ², Gulname Findik Guvendi ³, Selcuk Takir ⁴

¹ Department of Obstetrics and Gynecology, Giresun University, Giresun, Turkey

² Department of Cardiovascular Surgery, Giresun University, Giresun, Turkey

³ Department of Pathology, Kafkas University, Kars, Turkey

⁴ Department of Pharmacology, Giresun University, Giresun, Turkey

ARTICLE INFO

Article type:
Original article

Article history:
Received: Oct 15, 2017
Accepted: Sep 28, 2017

Keywords:
Ischemia
Ovary
Rats
Reperfusion
Torsion
Vitamin D

ABSTRACT

Objective(s): The aim of the present study is to investigate probable acute effects of vitamin D on ischemia-reperfusion injury in the rat ovary.

Materials and Methods: A group of 30 Wistar albino rats was divided into five groups of 6 each. Group 1: underwent laparotomy only and the ovaries were removed. Group 2: 3-hr ischemia followed by excision of the ovaries. Group 3: 3-hr ischemia and 3-hr reperfusion and the ovaries were removed. Group 4: vitamin D was administered 30 min prior to the 3-hr of ischemia and the ovaries were excised at the end of ischemia period. Group 5: vitamin D was administered 30 min prior to the 3-hr of ischemia and 3-hr reperfusion then the ovaries were removed at the end of reperfusion. The ovaries excised in each group also underwent biochemical and histopathologic analysis. MDA (malondialdehyde), SOD (superoxide dismutase), NO (nitric oxide), TAS (total antioxidant score), TOS (total oxidant score) were analyzed as biochemical parameters.

Results: There were no significant differences between groups in TAS, TOS, or OSI ($P>0.05$). MDA levels were lower in the vitamin D treatment groups especially in group 5, significantly ($P<0.05$). In the histopathologic evaluation, we established that an improvement with vitamin D treatment. According to tissue injury scores, vascular congestion score was significantly different between group 3 and 5 ($P<0.05$).

Conclusion: Vitamin D seems an effective molecule for protection of ischemia-reperfusion injury in rat ovary. There is some significant improvement in oxidative damages with vitamin D treatment.

► Please cite this article as:

Tokgoz VY, Sipahi M, Keskin O, Guvendi GF, Takir S. Protective effects of vitamin D on ischemia-reperfusion injury of the ovary in a rat model. Iran J Basic Med Sci 2018; 21:593-599. doi: 10.22038/IJBMS.2018.26914.6581

Introduction

Ovarian torsion is a rare and emergent surgical condition that is more common in women of childbearing age (1). Ovarian torsion is characterized with twists or turns of the ovary around its supporting ligaments so that it causes obstruction of the ovarian artery and vein and eventually results in ischemia of the ovary (2). It has serious consequences for women who plan to have more children because ovarian torsion has serious ovarian reserve complications. Early diagnosis and intervention is a very crucial decision. Treatment can be made by adnexectomy or detorsion of the ovary. Recently, ovarian detorsion is the preferred method for protecting the ovary of women who are of childbearing age (3). Ischemia causes hypoxic damage and after detorsion, blood supply may ameliorate the ovary while the reperfusion period leads to excessive production of reactive oxygen species (ROS) (4, 5). Reperfusion deteriorates the ischemic damage at the cellular level with reactive oxygen radicals (6). These mediators affect the cell membrane lipids and lead to increase in toxic products such as malondialdehyde (MDA) (7). However, ROS decreases natural antioxidants, glutathione (GSH) and superoxide dismutase (SOD), as well as increasing oxidant molecules (8).

Some antioxidant and anti-inflammatory agents were

tried to prevent tissue injury of ovaries caused by the ischemia-reperfusion procedure. Many studies have established some data to detect the antioxidant and anti-inflammatory effects of drugs (9-12). On the other hand, most of the medications cannot be used in clinical practice, unfortunately. An ideal drug should be safe and suitable for administration parenterally because it must protect the ovary quickly before the detorsion procedure.

Vitamin D is a protein that is associated with bone metabolism, but recently a wide range of activities was identified. Vitamin D and especially 1, 25 (OH)₂D₃, (1,25 dihydroxy vitamin D₃), which is the active form of vitamin D plays an important role in human metabolism (13). Vitamin D treatment decreases the ischemia-reperfusion injury after myocardial infarction with anti-inflammatory and anti-apoptotic actions (14). Moreover, vitamin D contributes to the regeneration of injured muscles (15). Deficiency of vitamin D is associated with the increase in oxidative stress and the apoptosis process (16). Pretreatment with vitamin D₃ has protective effects on ischemia-reperfusion injury of kidneys and hepatic tissues (17, 18).

In this study, we aimed to investigate probable acute effects of vitamin D on the ischemia-reperfusion model in rat ovary.

*Corresponding author: Vehbi Yavuz Tokgoz. Department of Obstetrics and Gynecology, Giresun University, Giresun, Turkey. Tel: +904543101600; Email: mdtokgoz@hotmail.com

Materials and Methods

Study and experimental design

In this study, a total of 30 adult, female Wistar albino rats weighing between 200–250 g were used. The experimental protocols and procedures were approved by the Animal Care and Local Ethics Committee of Giresun University (No: 2015/10). The animals were fed standardized pellets and water and food were given *ad libitum*. The animals were housed in steel cages in pairs and environment temperature was controlled at 22 ± 2 °C with 12/12 hr light-dark cycles. Rats were randomized before the procedure and were divided into five groups of 6 rats each. In each group, rats were anesthetized by intraperitoneal administration of 50 mg/kg ketamine hydrochloric acid (Ketalar; Eczacibasi Warner-Lambert Ilac Sanayi, Levent, Istanbul, Turkey) and 10 mg/kg xylazine hydrochloric acid (Rompun; Bayer Sisli, Istanbul, Turkey). Vitamin D₃ 1 ml, 7.5 mg (300000 IU) (Devit-3 amp; Deva Holding, Buyukcekmece, Istanbul, Turkey) was administered subcutaneously 30 min before the procedure. After anesthesia laparotomy was performed. Surgical procedures were made under sterile conditions. Laparotomy was performed with longitudinal 2.5 cm midline incision of the lower abdomen, and the uterine horns and adnexa were located. Ischemia procedure was made by suturing the adnexal regions from 0.5 cm above and 0.5 cm below with 4-0 Vicryl. Reperfusion was provided after ischemia of 3 hr duration by removal of sutures. Ovaries were removed after procedures. The left ovary was excised and stored under suitable conditions for biochemical analysis. The right ovary was excised and then put into a formaldehyde solution for pathologic examination. In group 1 (sham group), only laparotomy was performed and ovaries were removed. In group 2 (ischemia group), bilateral ovarian ischemia was performed by laparotomy and incision was closed for 3 hr. After the ischemia period, ovaries were excised with the second laparotomy. In group 3 (ischemia-reperfusion group), ischemia was performed as in group 2 and after 3 hr, reperfusion was provided with the removal of the sutures. Following the 3 hr reperfusion period, ovaries were removed surgically. In group 4 (vitamin D-ischemia group), vitamin D₃ was administered subcutaneously 30 min prior to laparotomy and then 3 hr ischemia procedure was performed and ovaries were removed surgically as in group 2. In group 5 (vitamin D-ischemia reperfusion group), vitamin D₃ was administered subcutaneously 30 min prior to laparotomy afterward ischemia-reperfusion process was made similar to group 3 and ovaries were excised surgically.

Biochemical analysis

MDA (malondialdehyde), SOD (superoxide dismutase), NO (nitric oxide), TAS (total antioxidant score), and TOS (total oxidant score) were analyzed as biochemical parameters. Left ovaries were kept at -80 °C in Eppendorf tubes until the biochemical analysis. After thawing the ovarian tissues a working solution was added and then the samples were homogenized with a homogenizer. After homogenization, centrifugation procedure was performed at 3000 rpm for 5 min. Supernatants were analyzed using the Rel Assay E autoanalyzer for TAS

and TOS examination. MDA, SOD, and NO were analyzed with ELISA kits by Rel Assay. Rel Assay E autoanalyzer was described below.

TAS levels were measured using commercially available kits (Relassay, Turkey). Erel previously described TAS values against free radicals with a fully automatic method (19). This assay kit has a very low error rate that is lower than 3%. The results were presented as mmol Trolox equivalent/l.

TOS levels were measured using suitable kits (Relassay, Turkey). In this method, the oxidation reaction was raised by glycerol molecules present in the reaction medium. The color intensity was related to the total amount of oxidant molecules present in the sample. The results of the evaluation were established in terms of micromolar hydrogen peroxide equivalent per liter ($\mu\text{mol H}_2\text{O}_2$ equivalent/l).

The ratio of TOS to TAS was determined as the oxidative stress index (OSI). For calculation, the resulting unit of TAS was converted to $\mu\text{mol/l}$, and the OSI value was calculated according to the following formula: $\text{OSI (arbitrary unit)} = \text{TOS } (\mu\text{mol H}_2\text{O}_2 \text{ equivalent/L}) / \text{TAC } (\mu\text{mol Trolox equivalent/L})$ (20).

Histopathological analysis

Right ovaries were put separately into a formaldehyde solution. Ovaries were fixed in a 10% formalin solution for 24–48 hr for histological examination. After the routine process, ovarian tissues were embedded in paraffin, and paraffin blocks of 4–5 μm thickness were cut with a microtome. All slides and sections were stained with Hematoxylin and Eosin (H&E). A pathologist who was blind to the study groups evaluated the samples. Sections were examined and photographed under a light microscope. A scoring system was used to determine the histopathologic changes. Follicular degeneration, edema, congestion, and hemorrhage were evaluated. According to the histopathological evaluation system, each ovarian tissue was scored from 0 to 3 (0: no pathologic findings, 1: mild pathologic findings, 2: moderate pathologic findings, and 3: severe pathologic findings) (21).

Statistical analysis

The statistical analysis was evaluated using Statistical Package for the Social Sciences (SPSS) version 20.0 (IBM Corp., New York, USA) for Mac. Normality test was performed with Kolmogorov-Smirnov test, and ANOVA test was performed for data that were normally distributed. The data that were not normally distributed were analyzed using nonparametric analysis, and statistical significance was determined by Kruskal-Wallis followed by Bonferroni-corrected Mann-Whitney U test. *P*-values <0.05 were considered statistically significant.

Results

We evaluated biochemical and histopathological parameters to determine the efficacy of vitamin D on ischemia and reperfusion injury of rat ovaries. Oxidative parameters and biochemical results were shown in Table 1. There were no significant differences between the groups for TAS, TOS, and OSI levels ($P > 0.05$).

Table 1. Oxidative parameters and biochemical results of groups

	Group 1	Group 2	Group 3	Group 4	Group 5	P
TAS (mmol Trolox equivalent/l)	0.89±0.14	0.85±0.19	0.91±0.14	0.90±0.16	1.05±0.17	0.29†
TOS ($\mu\text{mol H}_2\text{O}_2$ Eqiv./l)	14.88±4.44	18.21±3.57	17.53±5.53	15.92±3.32	22.46±7.00	0.71†
OSI (arbitrary unit)	2.18±1.15	2.95±1.80	2.48±1.49	1.77±0.30	2.08±0.41	0.51†
SOD (ng/ml)	3.32±1.74	4.33±1.65	4.24±1.62	7.25±1.93	6.30±0.17	0.70†
MDA ($\mu\text{mol/l}$)	2.15±0.55	2.32±0.90 ^a	1.69±0.34 ^b	2.31±0.86 ^c	1.26±0.15	<0.05†
NO (Umol/l)	1.93±0.95	1.16±0.12	1.74±0.26	1.46±0.67	1.33±0.22	0.01†

TAS Total antioxidant status, TOS Total oxidant status, OSI Oxidative stress index, SOD Superoxide dismutase, MDA Malondialdehyde, NO Nitric oxide. Values are expressed as mean± standard deviation (SD). † Kruskal-Wallis Test a,b,c Mann-Whitney U Test; ^a *P*-value<0.05, Group 2 vs Group 5; ^b *P*-value <0.05, Group 3 vs Group 5; ^c *P*-value <0.05, Group 4 vs Group 5

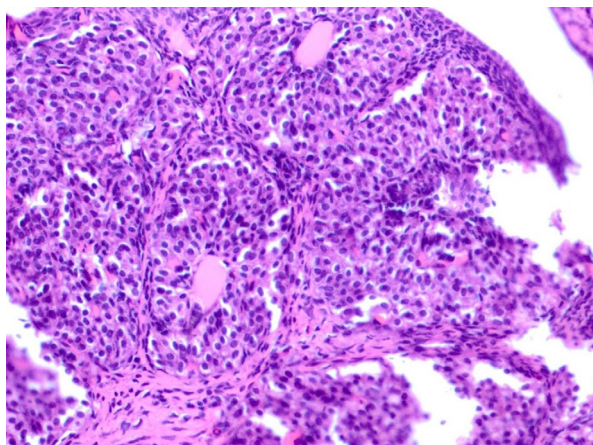


Figure 1. Normal histologic structure in the sham group, Hematoxylin and Eosin (H&E) staining (40x)

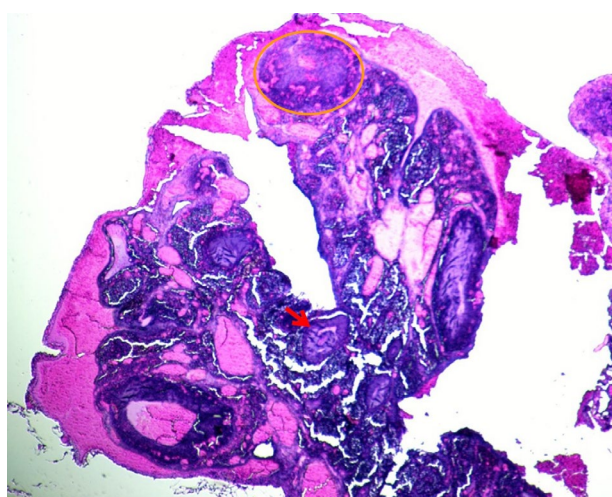


Figure 2. Group 2, ischemia group; significant degeneration and vascular congestion, Hematoxylin and Eosin (H&E) staining (10x). Degeneration (inside the orange circle), secondary follicle (red arrow)

When we compared the TAS values between group 2 (ischemia group) and group 4 (vitamin D-ischemia group), we found a little increase in group 4 but it was not significantly different. Similarly, group 5 (vitamin D-ischemia and reperfusion group) had higher TAS values than group 3 (ischemia and reperfusion group) but

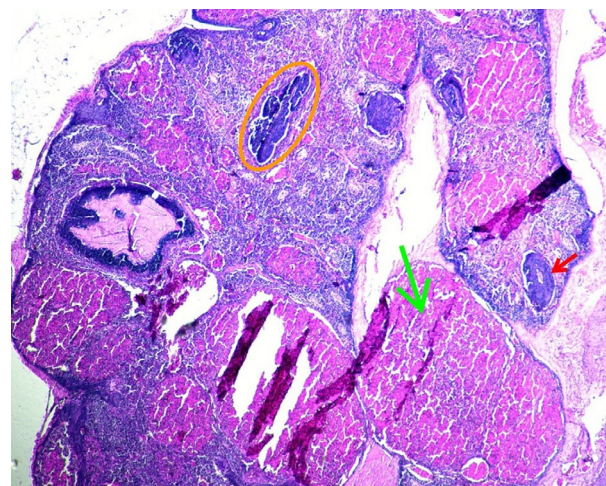


Figure 3. Group 3, ischemia-reperfusion; significant vascular congestion, degenerated follicles, Hematoxylin and Eosin (H&E) staining (20x). Primary follicle (inside the orange circle), corpus luteum (green arrow), secondary follicle (red arrow)

not significantly. When we compared groups in terms of MDA levels, a statistically significant difference was established ($P < 0.05$), especially we found significant differences between group 2 vs group 5, group 3 vs group 5 and group 4 vs group 5 ($P < 0.05$). SOD levels between groups were not different significantly ($P > 0.05$).

Histopathological evaluation showed significant improvement with vitamin D treatment, especially in vascular congestion. Follicle degeneration and vascular congestion attenuated with vitamin D treatment. Group 5 (vitamin D-ischemia reperfusion group) had minimal congestion and degeneration compared with group 3 (ischemia-reperfusion group). Similarly, there was a significant difference between groups 4 and 2 (Figure 1, Figure 2, Figure 3, Figure 4 and Figure 5). Histopathological tissue injury scores were determined as explained above. Tissue injury scores of the groups were shown in Table 2. We compared follicle degeneration, vascular congestion, edema, and inflammation between groups. We did not find any significant differences in follicle degeneration, edema, and inflammation ($P > 0.05$). Groups 4 and 5 had less follicle degeneration than groups 2 and 3, respectively,

Table 2. Comparison of study groups according to tissue injury scores

	Group 1	Group 2	Group 3	Group 4	Group 5	P
Follicle Degeneration	0.83±0.40	1.00±0.00	1.00±0.00	0.83±0.40	0.83±0.40	0.73†
Vascular Congestion	1.66±0.81	2.00±0.63 ^d	3.00±0.00	2.33±0.81	1.66±1.21 ^e	0.04†
Edema	1.00±0.00	1.00±0.00	1.00±0.00	1.33±0.51	1.33±0.51	0.14†
Inflammation	0.00	0.00	0.16±0.40	0.16±0.40	0.00	0.56†

Values are expressed as mean±standard deviation (SD). † Kruskal-Wallis Test; d,e Mann-Whitney U Test; ^d P-value <0.05, group 2 vs group 3; ^e P-value <0.05, group 3 vs group 5

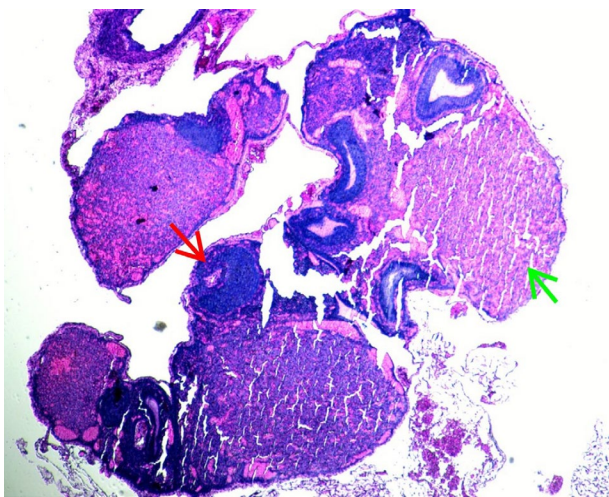


Figure 4. Group 4, vitamin D-Ischemia; minimal degeneration, Hematoxylin and Eosin (H&E) staining (10x). Secondary follicle (red arrow), corpus luteum (green arrow)

but the mean scores did not reach any significance. Mean scores of vascular congestion were different significantly between groups ($P<0.05$). We compared the difference for vascular congestion; according to the results, vascular congestion was markedly higher in group 3 compared with group 2 ($P<0.05$). We also obtained a significant difference between groups 3 and 5 in terms of vascular congestion scores. Group 5 (vitamin D-ischemia and reperfusion group) had a significantly lower score than group 3 (ischemia and reperfusion group) ($P<0.05$). According to these results, vitamin D treatment significantly improved tissue injury in rat ovaries.

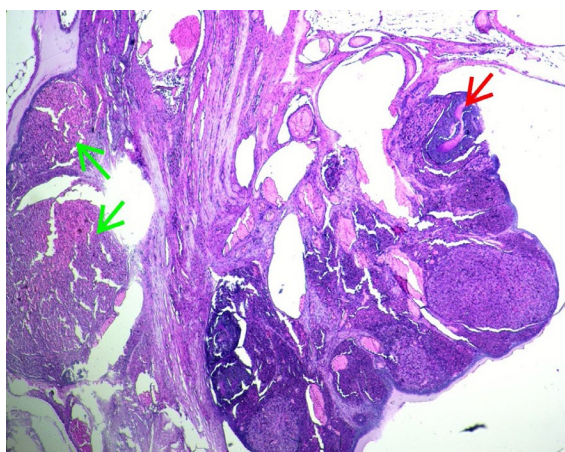


Figure 5. Group 5, vitamin D-ischemia-reperfusion; significant improvement in vascular congestion and follicle degeneration, Hematoxylin and Eosin (H&E) staining (10x). Secondary follicle (red arrow), corpus luteum (green arrow)

Discussion

To the best of our knowledge, this is the first study that shows the effects of vitamin D in an ovarian ischemia-reperfusion model. We established that vitamin D had effective results on torsion-detorsion model of the ovary in a rat model. Vitamin D had beneficial effects on lipid peroxidation process of the ischemia-reperfusion procedure, especially. Our objective was to detect the probable acute effects of vitamin D in the present study. We found significant vitamin D effects in terms of some biochemical and histopathological parameters; although not all parameters were improved significantly in the treated group compared to the untreated group.

In the torsion procedure, oxidative mechanisms are activated with lack of oxygen. When the blood flow is restored with detorsion, reperfusion process is started and then reperfusion injury is induced by the large number of ROS (22). Lipid peroxidation is a critical situation in cell membrane injury with free oxygen radicals (23). In the lipid peroxidation, MDA, an oxidative damage marker, arose and broke the cell membrane permeability, therefore, damaging the tissue (9, 24). MDA is also an important mediator for the failure of the antioxidant mechanisms. However, the body has a balance between oxidant and antioxidant mechanisms. Antioxidant systems such as enzymatic and non-enzymatic antioxidants scavenge ROS to prevent oxidative damage in tissues. When the oxidant mechanisms dominate that balance system for any reason, it leads to lipid peroxidation and tissue damage (25). SOD is one of the important antioxidant enzymes. There are several studies that demonstrate decline in SOD activity with the ovarian ischemia-reperfusion procedure (26, 27). NO is another molecule that has antioxidant and antineutrophilic actions (28). In the present study, we found that MDA levels were significantly high in the ischemia group. Similar to the literature, SOD values were lower in the ischemia and reperfusion group than in the treatment groups; but it did not reach any significance.

Some oxidative parameters such as TAS and TOS were also used to determine the effects of damage and treatment modalities. Yurtcu *et al.* showed the TAS and TOS levels in torsion and detorsion model of the ovary (11). Oxidant levels were high and antioxidant levels were low in the ischemia and reperfusion group before treatment. Similarly, Gungor *et al.* used TAS and TOS levels to mark the effect of Omegaven treatment on the oxidative damage (29).

There are some studies that showed the effects of

antioxidant molecules on the ischemia and reperfusion model. Tissue damage of the ovary might be decreased by antioxidant molecules, thus diminishing of the ovarian reserve can be prevented. Gungor *et al.* reported that tissue injury was corrected with a high dose of Omegaven (omega-3 fatty acids)(29). Thiamin, vitamin B1, and thiamine pyrophosphate were also used for preventing the ischemia/reperfusion injury of the ovary. In a study, the positive outcomes related to thiamine pyrophosphate treatment were established (30). Erythropoietin (EPO) was tested in a study to detect the antioxidant efficacy of ovary, and oxidative damage was reduced histopathologically and biochemically by EPO treatment (27). Some vitamins have been tried to determine the antioxidant and antiapoptotic actions on oxidative injury. It was found that vitamin E supplementation ameliorated the apoptotic changes of ovary due to the ischemia and reperfusion process (12). Moreover, there are several studies reporting that vitamin D and vitamin D receptor activator have protective effects on ischemia and reperfusion injury. It was established that vitamin D₃ protects the kidney from reperfusion injury (31). Similarly, it was determined that vitamin D receptor activator paricalcitol has beneficial effects on renal ischemia-reperfusion damage, in a study (32). Seif and Abdelwahed have reported that vitamin D supplementation protects the liver against ischemia and reperfusion injury with antioxidant and antiapoptotic mechanisms (18).

These studies motivated and encouraged us so from this point of view, we aimed to detect the efficacy of vitamin D on ischemia-reperfusion injury on the rat ovary. We found that vitamin D administration prior to the ischemia-reperfusion process has beneficial effects on oxidative damage of the ovary. MDA levels were low in the vitamin D administered group. Especially, there was a significant difference between only ischemia-reperfusion group and the vitamin D administered ischemia-reperfusion group. Similar to our study, it was shown that EPO administration decreased the MDA levels in the ischemia-reperfusion group (27). It was found that ethyl-pyruvate administration decreased MDA levels in rats with ovarian torsion, significantly (33). Oxytocin was evaluated in reducing the ovarian damage in a study and MDA levels were lower in torsion/detorsion and oxytocin groups (34). Some previous studies indicate that low MDA levels show the efficacy of the antioxidant agents (35-37).

The reduction of SOD activity probably indicated depletion of the antioxidant enzyme by free oxygen radicals. SOD levels were increased with EPO treatment in the rat ovary, significantly (27). In an experimental study, researchers showed improved SOD activity with the bosentan which is an endothelin receptor antagonist (38). Similar to these findings, we demonstrated that SOD activity increased in the vitamin D treatment group compared with the ischemia and ischemia-reperfusion groups, but not significantly.

TAS and TOS levels were measured to determine the effect of vitamin D on ischemia and reperfusion injury. We did not find any significant differences between groups in terms of TAS and TOS values. Conversely, Yurtcu *et al.* observed statistically significant differences

(11). Furthermore, Gungor *et al.* found no significant differences in TAS and TOS levels between groups (29).

In the present study, we found that vitamin D administration improved the lipid peroxidation process in the ischemia-reperfusion procedure. MDA levels reduced significantly in the vitamin D group and SOD activity increased in the treatment group, but not significantly. Vitamin D attenuated oxidative damage, therefore, MDA which is a good marker of lipid peroxidation decreased in the vitamin D group. Our aim is to detect the acute efficacy of vitamin D administration on torsion-detorsion of the ovary. Acute effect of vitamin D emerged by the significant decrease of MDA and not significant increase of SOD activity, in our study. Similarly, Seif and Abdelwahed showed MDA decline with vitamin D use in the liver ischemia and reperfusion process (18).

When we evaluated the histopathological findings, we observed that the vascular congestion score was significantly different in the vitamin D treatment group compared with the ischemia-reperfusion group ($P=0.04$). However, other histopathological findings, i.e., follicle degeneration, edema, and inflammation were not statistically different between groups. In previous studies, the authors found a marked improvement in histopathological findings with antioxidant treatment. Tissue injury scores were used to evaluate the histopathology in several studies (11, 29, 34). Similarly, they found significant improvement in treatment groups according to vascular congestion scores. Contrary to our study, they also found significant differences in follicle degeneration, edema, and hemorrhage scores. When the ischemia-reperfusion process occurred, inflammatory cells cause increased free oxygen radicals that led to tissue injury by inflammatory mechanisms (39). Another study focused on a treatment modality to avoid apoptosis rather than transient oxidative stress (40). In this study, it was emphasized that anti-inflammatory and antioxidant agents may prevent irreversible changes like apoptosis. We planned to study with an agent that has anti-inflammatory and antiapoptotic actions. For this reason, we used vitamin D to detect the efficacy in ischemia-reperfusion injury. A study evaluated procalcitonin (vitamin D receptor activator) to determine whether this agent is effective in ischemia-reperfusion injury of the kidney (32). SOD levels were found significantly higher in the procalcitonin group than in the ischemia-reperfusion group. Bae *et al.* established that vitamin D has cardioprotective effects through antiapoptotic and anti-inflammatory mechanisms (14). Similarly, it was determined that vitamin D ameliorates ischemia-reperfusion injury in rat kidneys (17). In an experimental study, Seif and Abdelwahed demonstrated that attenuation of oxidative damage is maintained by vitamin D supplementation (18). A significant decrease of MDA levels was maintained with vitamin D administration similar to our study. However, the exact mechanism of vitamin D for apoptosis in ovarian ischemia-reperfusion injury has not been clearly understood.

As mentioned above, there are several studies related to vitamin D in ischemia-reperfusion injury. All studies applied the vitamin D treatment at least 7 weeks

before the surgical procedure. But our objective was to determine the probable acute effect of vitamin D on ovarian ischemia-reperfusion injury so we administered vitamin D prior to the procedure. There are several pharmacological agents to prevent reperfusion injury, but unfortunately, most of them cannot be used in clinical practice for ovarian torsion cases. Furthermore, vitamin D can be used parenterally, and it is a safe, inexpensive, and accessible agent. Parenteral usage is one of its advantages in an emergency situation.

Conclusion

Vitamin D seems an effective molecule for protection of ischemia and reperfusion injury of the ovary. We determined significant beneficial effects in ischemia/reperfusion injury of the ovary with vitamin D administration, especially on MDA levels and vascular congestion. Although some improvement is obtained, there are no statistically significant differences in other biochemical and histopathological findings. We thought that it might be related to the long elimination and action time of vitamin D. Further studies are needed to evaluate the clinical applications, effects, and doses of vitamin D. We hope that this study and outcomes will inspire others to make further studies.

Acknowledgment

This work was supported by the Scientific Investigation Projects Coordination Unit [project no: 200515-34] of Giresun University, Giresun, Turkey.

Conflicts of Interest

We declare that we have no conflicts of interest.

References

- Hibbard L. Adnexal torsion. *Am J Obstet Gynecol* 1985;152:456-461.
- Becker JH, de Graaff J, Vos MC. Torsion of the ovary: a known but frequently missed diagnosis. *Eur J Emerg Med* 2009;16:124-126.
- Chen M, Chen CD, Yang YS. Torsion of the previously normal uterine adnexa. Evaluation of the correlation between the pathological changes and the clinical characteristics. *Acta Obstet Gynecol Scand* 2001;80:58-61.
- Huchon C, Fauconnier A. Adnexal torsion: a literature review. *Eur J Obstet Gynecol Reprod Biol* 2010;150: 8-12.
- McCord JM. Oxygen-derived free radicals in postischemic tissue injury. *N Engl J Med* 1985;312:159-163.
- Zimmerman BJ, Granger DN. Reperfusion injury. *Surg Clin North Am.* 1992;72: 65-83.
- Sozer S, Diniz G, Lermioglu F. Effects of celecoxib in young rats: histopathological changes in tissues and alterations of oxidative stress/antioxidant defense system. *Arch Pharm Res* 2011;34: 253-259.
- Tok A, Sener E, Albayrak A, Cetin N, Polat B, Suleyman B, et al. Effect of mirtazapine on oxidative stress created in rat kidneys by ischemia-reperfusion. *Ren Fail* 2012;34: 103-110.
- Akdemir A, Erbas O, Ergenoglu M, Ozgur Yeniel A, Oltulu F, Yavasoglu A, et al. Montelukast prevents ischaemia/reperfusion-induced ovarian damage in rats. *Eur J Obstet Gynecol Reprod Biol* 2014;173: 71-76.
- Abali R, Tasdemir N, Yuksel MA, Guzel S, Oznur M, Nalbantoglu B, et al. Protective effect of infliximab on ischemia/reperfusion injury in a rat ovary model: biochemical and histopathologic evaluation. *Eur J Obstet Gynecol Reprod Biol* 2013;171: 353-357.
- Yurtcu E, Togrul C, Ozyer S, Uzunlar O, Karatas YH, Seckin KD, et al. Dose dependent protective effects of vardenafil on ischemia-reperfusion injury with biochemical and histopathologic evaluation in rat ovary. *J Pediatr Surg* 2015; 50:1205-1209.
- Sapmaz-Metin M, Topcu-Tarladacalisir Y, Uz YH, Inan M, Omurlu IK, Cerkezkyabekir A, et al. Vitamin E modulates apoptosis and c-jun N-terminal kinase activation in ovarian torsion-detorsion injury. *Exp Mol Pathol* 2013; 95:213-219.
- Walentowicz-Sadlecka M, Sadlecki P, Walentowicz P, Grabiec M. [The role of vitamin D in the carcinogenesis of breast and ovarian cancer]. *Ginekol Pol* 2013; 84: 305-308.
- Bae S, Singh SS, Yu H, Lee JY, Cho BR, Kang PM. Vitamin D signaling pathway plays an important role in the development of heart failure after myocardial infarction. *J Appl Physiol* 2013;114:979-987.
- Stratos I, Li Z, Herlyn P, Rotter R, Behrendt AK, Mittlmeier T, et al. Vitamin D increases cellular turnover and functionally restores the skeletal muscle after crush injury in rats. *Am J Pathol* 2013;182: 895-904.
- Assalin HB, Rafacho BP, dos Santos PP, Ardisson LP, Roscani MG, Chiuso-Minicucci F, et al. Impact of the length of vitamin D deficiency on cardiac remodeling. *Circ Heart Fail* 2013;6: 809-816.
- Sinanoglu O, Sezgin G, Ozturk G, Tuncdemir M, Guney S, Aksungar FB, et al. Melatonin with 1,25-dihydroxyvitamin D3 protects against apoptotic ischemia-reperfusion injury in the rat kidney. *Ren Fail.* 2012; 34:1021-1026.
- Seif AA, Abdelwahed DM. Vitamin D ameliorates hepatic ischemic/reperfusion injury in rats. *J Physiol Biochem* 2014; 70:659-666.
- Erel O. A new automated colorimetric method for measuring total oxidant status. *Clin Biochem.* 2005;38:1103-1111.
- Harma M, Harma M, Erel O. Increased oxidative stress in patients with hydatidiform mole. *Swiss Med Wkly* 2003; 133:563-566.
- Guyen S, Muci E, Unsal MA, Yulug E, Alver A, Kadioglu Duman M, et al. The effects of carbon dioxide pneumoperitoneum on ovarian blood flow, oxidative stress markers, and morphology during laparoscopy: a rabbit model. *Fertil Steril* 2010;93 1327-1332.
- Lin E, Lowry S, Calvano S. The systemic response to injury. *Principles of Surgery.* 7th ed. New York: McGraw-Hill; 1999.
- White BC, Grossman LI, Krause GS. Brain injury by global ischemia and reperfusion: a theoretical perspective on membrane damage and repair. *Neurology* 1993;43:1656-1665.
- Erkanli Senturk G, Erkanli K, Aydin U, Yucel D, Isiksacan N, Ercan F, et al. The protective effect of oxytocin on ischemia/reperfusion injury in rat urinary bladder. *Peptides* 2013; 40: 82-88.
- Lee DM, Hoffman WH, Carl GF, Khichi M, Cornwell PE. Lipid peroxidation and antioxidant vitamins prior to, during, and after correction of diabetic ketoacidosis. *J Diabetes Complications* 2002; 16:294-300.
- Yigiter M, Halici Z, Odabasoglu F, Keles ON, Atalay F, Unal B, et al. Growth hormone reduces tissue damage in rat ovaries subjected to torsion and detorsion: biochemical and histopathologic evaluation. *Eur J Obstet Gynecol Reprod Biol* 2011; 157: 94-100.
- Bakan V, Ciralik H, Tolun FI, Atli Y, Mil A, Ozturk S. Protective effect of erythropoietin on torsion/detorsion injury in rat model. *J Pediatr Surg* 2009; 44:1988-1994.
- Ferdinandy P. Peroxynitrite: just an oxidative/nitrosative stressor or a physiological regulator as well? *Br J Pharmacol* 2006;148: 1-3.
- Gungor AN, Turkon H, Albayrak A, Ovali M, Islimye M, Gencer M, et al. Does Omegaven have beneficial effects on a rat model of ovarian ischemia/reperfusion? *Eur J Obstet Gynecol*

- Reprod Biol 2014; 181: 240-245.
30. Demiryilmaz I, Sener E, Cetin N, Altuner D, Akcay F, Suleyman H. A comparative investigation of biochemical and histopathological effects of thiamine and thiamine pyrophosphate on ischemia-reperfusion induced oxidative damage in rat ovarian tissue. Arch Pharm Res 2013; 36:1133-1139.
31. Tan X, Wen X, Liu Y. Paricalcitol inhibits renal inflammation by promoting vitamin D receptor-mediated sequestration of NF-kappaB signaling. J Am Soc Nephrol 2008;19:1741-1752.
32. Azak A, Huddam B, Haberal N, Kocak G, Ortabozkoyun L, Senes M, et al. Effect of novel vitamin D receptor activator paricalcitol on renal ischaemia/reperfusion injury in rats. Ann R Coll Surg Engl 2013; 95: 489-494.
33. Caglayan EK, Caglayan K, Gocmen AY, Cinar H, Seckin L, Seckin S, et al. Protective effect of ethyl pyruvate on ischemia-reperfusion injury in rat ovary: biochemical and histopathological evaluation. Eur J Obstet Gynecol Reprod Biol 2014; 182: 154-159.
34. Akdemir A, Erbas O, Gode F, Ergenoglu M, Yeniel O, Oltulu F, et al. Protective effect of oxytocin on ovarian ischemia-reperfusion injury in rats. Peptides 2014; 55: 126-130.
35. Bozkurt S, Arikan DC, Kurutas EB, Sayar H, Okumus M, Coskun A, et al. Selenium has a protective effect on ischemia/reperfusion injury in a rat ovary model: biochemical and histopathologic evaluation. J Pediatr Surg 2012; 47:1735-1741.
36. Ergun Y, Koc A, Dolapcioglu K, Akaydin Y, Dogruer G, Kontas T, et al. The protective effect of erythropoietin and dimethylsulfoxide on ischemia-reperfusion injury in rat ovary. Eur J Obstet Gynecol Reprod Biol 2010;152: 186-190.
37. Sayyah-Melli M, Rashidi MR, Kaseb-Ganeh M, Rashtchizadeh N, Taghavi S, Ouladsahebmadarek E, et al. The effect of erythropoietin against oxidative damage associated with reperfusion following ovarian detorsion. Eur J Obstet Gynecol Reprod Biol 2012;162:182-186.
38. Sengul O, Ferah I, Polat B, Halici Z, Bayir Y, Yilmaz M, et al. Blockade of endothelin receptors with bosentan limits ischaemia/reperfusion-induced injury in rat ovaries. Eur J Obstet Gynecol Reprod Biol 2013;170:458-463.
39. Liou KT, Shen YC, Chen CF, Tsao CM, Tsai SK. Honokiol protects rat brain from focal cerebral ischemia-reperfusion injury by inhibiting neutrophil infiltration and reactive oxygen species production. Brain Res 2003;992:159-166.
40. Cakir Gungor AN, Gencer M, Karaca T, Hacivelioglu S, Uysal A, Korkmaz F, et al. The effect of hesperetin on ischemia-reperfusion injury in rat ovary. Arch Gynecol Obstet 2014; 290: 763-769.