

RESEARCH ARTICLE

The Stabilising Effect of the Anterior Oblique Ligament to Prevent Directional Subluxation at the Trapeziometacarpal Joint of the Thumb: A Biomechanical Cadaveric Study

Mark R. McCann, MSc; Philippa A. Rust, MD; Robert Wallace, PhD

Research performed at The University of Edinburgh Anatomy Department, UK

Received: 15 August 2017

Accepted: 02 December 2017

Abstract

Background: The trapeziometacarpal joint (TMCJ) is inherently unstable, relying on ligament restraint to prevent subluxation. Subluxation of the thumb in a dorsoradial direction is often observed in clinical practice, either after acute ligament injury or more commonly with osteoarthritis (OA). This subluxation follows loss of function of trapeziometacarpal ligaments that stabilise this joint, resisting the deforming force of abductor pollicis longus (APL). The exact ligaments that stabilise and prevent the thumb from the pull of APL causing dorsoradial subluxation remain unknown, although the anterior oblique ligament (AOL) has been implicated. The aim of this study was to measure the direction of subluxation resisted by the AOL.

Methods: In this study we used cadaveric limbs and custom made biomechanical testing to measure the influence AOL has in stabilising the thumb against subluxation in three planes: radial, dorsal and dorsoradial. Three fresh frozen hands were dissected to expose the TMCJ, leaving all ligaments, capsule and APL attachment in place. The force required to create a displacement of 5mm between the first metacarpal and the trapezium in these three planes was measured before and after AOL division.

Results: The average force to displace in the dorsoradial plane prior to division was 6.68N, and a statistically significant reduction to 1.15N ($P<0.001$) was found after division of the AOL. A statistically significant increase in force ($P<0.001$) from 2.89N to 4.04N was seen in the radial plane, while no change was seen dorsally ($P=0.98$), with average forces of 2.74N and 2.62N found pre and post division.

Conclusion: There is clinical significance in reporting quantifiable data in this field, as subluxation of the thumb is often seen with OA. The results of our study provide support for surgical reconstruction of the AOL as the primary surgical stabilizer against dorsoradial subluxation of the thumb.

Level of evidence: III

Keywords: Anterior oblique ligament, Biomechanical testing, Thumb, Trapeziometacarpal joint, Stability, Subluxation

Introduction

Due to the trapezium's unique bony articulations, its connection to the first metacarpal forms a distinct 'saddle shape' known as the TMCJ. Although

this joint facilitates essential everyday activities that require pinch grip, its large range of movement leaves the thumb prone to subluxation in individuals who have

Corresponding Author: Philippa A. Rust, Hand Surgery Unit, St John's Hospital, Livingston, UK
Email: Philippa.Rust@nhslothian.scot.nhs.uk



THE ONLINE VERSION OF THIS ARTICLE
ABJS.MUMS.AC.IR

compromised trapeziometacarpal ligaments (1).

The anterior oblique ligament (AOL) attaches from the palmar tubercle of the trapezium to the palmar base of the first metacarpal (2). Subluxation of the thumb occurs after injury, i.e. with an intra-articular fracture at the base of the metacarpal (Bennett's type) or following dislocation and ligament injury at the TMCJ. The AOL is thought to be a major stabiliser of the TMCJ (3). The dorsoradial ligament has also been shown to be a stabilizer in clinical studies, and other studies have found the intra metacarpal ligament (IMC) to have substantial involvement (4, 5). The IMC was found to have a greater influence than the AOL in comparative studies (6). A more recent study applied physiological muscle loads to transected trapeziometacarpal ligaments and identified the dorsoradial ligament (DRL) as an important stabiliser of the TMCJ (7). Thus, there is no conclusive evidence providing a consistent and quantifiable measure of AOL's role in subluxation, as the studies that have investigated this have produced contradictory reports.

Subluxation of the thumb can be extremely painful and lead to weakness of pinch grip movements, such as turning a key. Loss of these functions can leave patients with significantly less independence. Treatment of chronic subluxation of the thumb varies from rehabilitation with splints and NSAID's to surgical procedures (8). Dorsoradial subluxation is

commonly observed in patients with OA at the TMCJ. It has therefore been suggested that subluxation may precede, and even be a causative factor in the development of OA. OA at the TMCJ is particularly common in middle-aged women. The treatment of OA with subluxation is ultimately surgical, and procedures such as a trapeziectomy carry a significant rehabilitation period for patients (9). In the case of TMCJ subluxation without OA (a Eaton Littler grade 1), a recent surgical study has proposed that AOL reconstruction using strips of flexor carpi radialis tendon is the most effective surgical technique (10).

This study aims to provide a quantifiable test of the role AOL has to play in dorsoradial subluxation. Thus, the stabilising role of AOL in preventing radial, dorsal and dorsoradial subluxation was assessed biomechanically before and after AOL division. Based on related research, we predict a significant decrease in force usually preventing instability on the dorsoradial plane following AOL division.

Materials and Methods

Before dissection, six of fresh-frozen hands were radiographed [Figure 1]. This ensured that there was no underlying pathology that might affect the results, such as osteoarthritis (OA) or malalignment at the TMCJ. Ultimately, 3 specimens showed no signs of OA upon x-ray

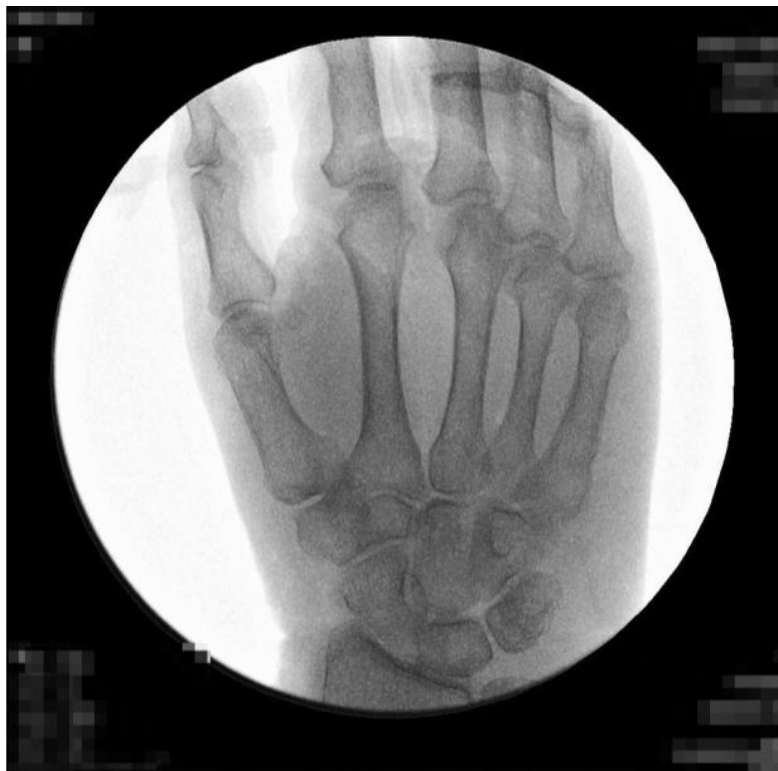

Figure 1. Radiographs of specimen 1 – the TMCJ shows no signs of OA and is a suitable candidate for dissection.

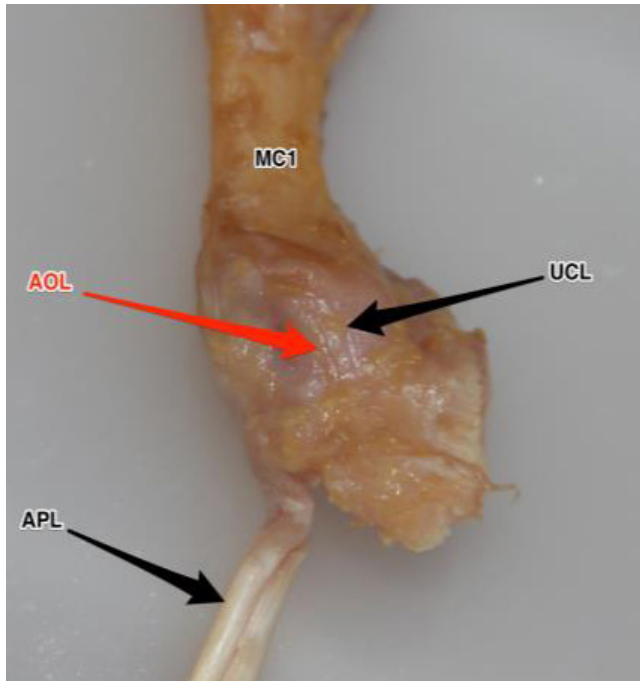


Figure 2. Left thumb. Fresh frozen specimen that has been fully dissected and disarticulated from the hand. AOL can be clearly seen (red arrow) attaching from the palmar tubercle of the trapezium to the palmar base of the first metacarpal. APL: tendon of abductor pollicis longus, MC1: first metacarpal, UCL: ulnar collateral ligament.

and were identified as suitable candidates for dissection with an average age of 81.3 (SD \pm 10.6).

Inclusion criteria: no sign radiological pathology, intact

joints and freshly frozen cadaveric material available with necessary consent. Exclusion criteria: evidence of OA/other pathology at TMCJ, or damaged TMCJ site.

Dissection of each specimen was carefully carried out as follows, with an example finished dissection shown [Figure 2]. Abductor pollicis longus was identified, preserved and carefully separated from extensor pollicis brevis. The thenar muscles were detached and reflected medially. At this point the TMCJ capsule could be identified, and additional care was taken to preserve and clean any subcutaneous tissue/muscle around the area. To disarticulate the thumb, the articulations of trapezio-scapoid and trapezio-trapezoid joints were identified. Final detachment of thumb was achieved by disarticulation of trapezio-trapezoid joint.

Biomechanical testing was carried out on a Zwick/Roell z005 (Zwick GmbH & Co, Ulm, Germany) mechanical testing machine using TestXpert V9.01 (Zwick GmbH & Co, Ulm, Germany) as the control and data capture software. The apparatus functioned such that multiple planes of movement could be assessed, including adduction, extension and opposition [Figure 3]. The thumb was securely clamped in place about the condyles of the metacarpal while the trapezium was affixed to a custom made jig attached to the machine crosshead [Figure 4].

The specimens were loaded by moving the trapezium at a rate of 5mm/min to a maximum deflection of 5mm. The load was removed at the same rate until the specimen returned to the starting position and this process was repeated 5 times. The values from the first elongation were discarded, as their primary purpose was to dampen any 'ligament strengthening effects' and ensure firm fitting of the thumb for the next tests (11). Therefore, 4 values of force were recorded in each of the three testing directions for each thumb, before and after intervention.

Clamps gripping the first metacarpal and trapezium held each thumb in place [Figure 4]. Figure 5 shows these

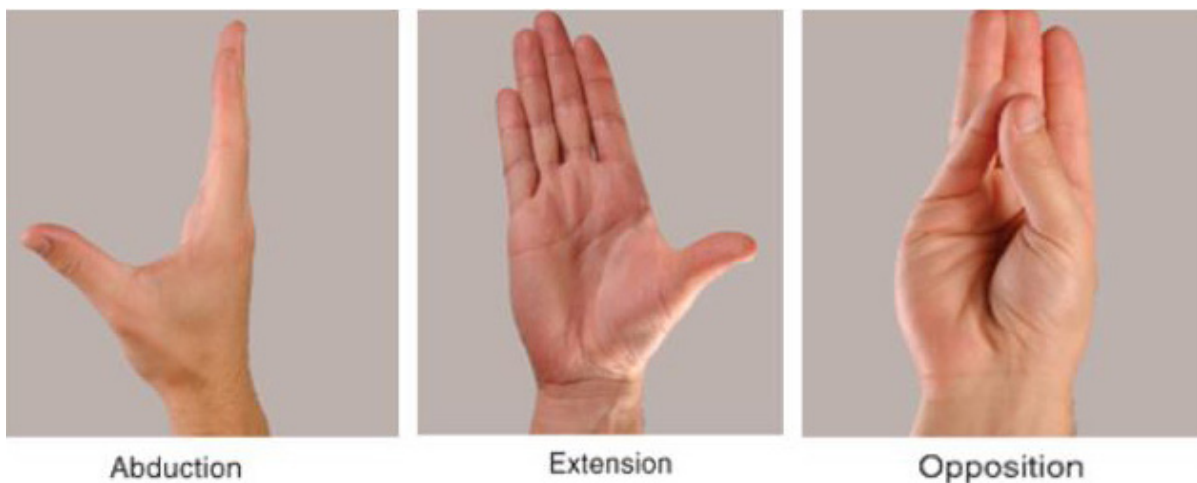


Figure 3. The 3 planes used during testing. Plane 1: Abduction/radial subluxation. Plane 2: Extension/dorsal subluxation. Plane 3: Dorsoradial, following the pull of APL and opposite of opposition. (Clinically Orientated Anatomy).



Figure 4. Each thumb was clamped tightly and subjected to mechanical testing. The clamp on the right (grey) applied deflection to the trapezium to recreate physiological movements. In this example, dorsal subluxation (extension) is tested.

directions. The thumb was positioned using the nail to define the dorsal and radial planes and the direction of pull of the APL to define the dorsoradial plane. The thumb was then subjected to displacement in each of these directions. In order to accurately recreate dorsoradial plane, superior surface of the APL would face directly upwards in the jig during testing to generate a movement of dorsoradial subluxation. Once data from all specimens was acquired, the AOL of each thumb specimen was

identified and divided ensuring that the underlying capsule and neighbouring ligaments were preserved. The testing protocol was then repeated as described above in all three planes.

Results

The results of these experiments are shown [Figure 6]. Pre and post division data is also displayed graphically according to testing plane [Figure 7]. This data was

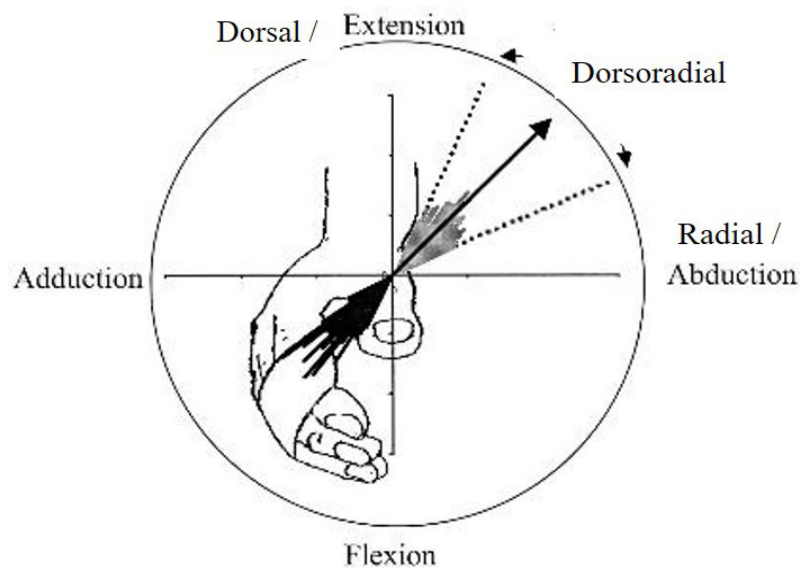


Figure 5. Directions of pull when the trapezium and first metacarpal were held in place by the jig.

Table 1. Collated force results for radial plane				
Radial subluxation/abduction	Pre		Post	
	Mean (N)	± SD	Mean	± SD
specimen 1	2.24	0.09	5.06	0.13
specimen 2	3.67	0.28	3.40	0.91
specimen 3	2.77	0.12	3.66	0.26
Average	2.89	0.62	4.04	0.91

Table 2. Collated force results for dorsal plane				
Dorsal subluxation/extension	Pre		Post	
	Mean (N)	± SD	Mean	± SD
specimen 1	3.08	0.22	3.30	0.84
specimen 2	4.20	0.33	3.36	0.26
specimen 3	0.94	0.18	1.21	0.03
Average	2.74	1.37	2.62	1.12

Table 3. Collated force results for dorsoradial plane				
Dorsoradial	Pre		Post	
	Mean (N)	± SD	Mean	± SD
specimen 1	6.25	0.17	0.68	0.04
specimen 2	4.84	0.22	0.58	0.06
specimen 3	8.92	0.05	2.18	0.08
Average	6.67	1.70	1.15	0.74

Figure 6. Tables 1 –3 collated forces for plane sof displacement of TMCJ pre and post AOL division.

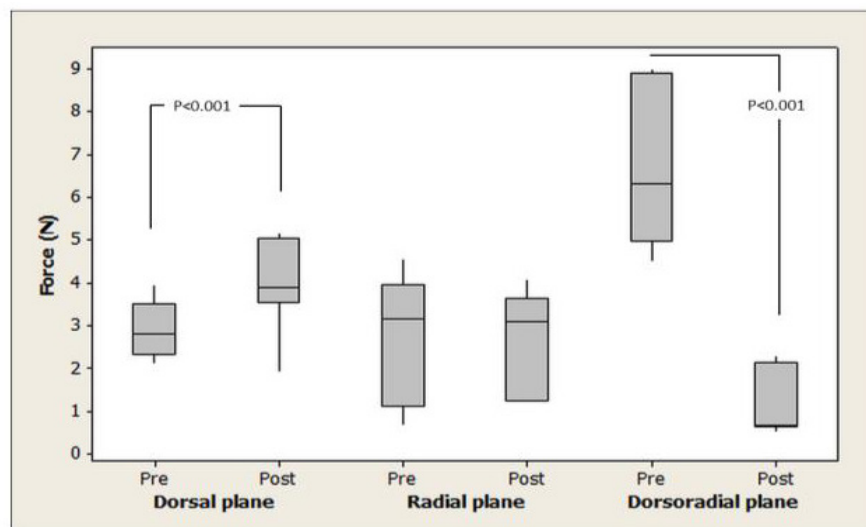


Figure 7. Mechanical testing results.

visually inspected for normality, as a normal distribution was not seen, statistical testing for non-parametric data was conducted by means of a Mann-Whitney test.

Discussion

In conclusion, the AOL significantly resists dorsoradial subluxation at the TMCJ in our cadaveric models. However it does not significantly reduce subluxation of the joint in a dorsal or radial plane. Using an intact APL tendon allowed this subluxation in the line of pull of APL to be tested, as dorsoradial subluxation occurs along the orientation of this tendon. In support of our hypothesis, all 3 specimens showed a significant reduction in force following AOL division in a dorsoradial plane. This demonstrates the major role AOL has in stabilizing the thumb against dorsoradial subluxation and APL action; without AOL influence, the thumb has greatly reduced resistance to dorsoradial subluxation.

This data clarifies the role of the AOL in stabilizing the TMCJ, as other studies have not assessed it as a stabiliser against dorsoradial subluxation. Although previous research examined the ligament stability of the TMCJ, noting the importance of the AOL, other studies had identified different ligaments such as dorsoradial and IMC as primary stabilisers (3, 4, 6, 12).

The current treatment for dorsoradial subluxation of the thumb is largely dependent on the physician's interpretation and the available resources (9). The data in this study can be used to support a current avenue of surgical research promoting AOL reconstruction as the primary intervention. The results of surgical research demonstrated that reconstruction of the AOL using a strip of flexor carpi radialis tendon was a useful method of restoring strength to pinch strength and reducing pain (10).

A further observation during biomechanical testing was the natural variation in strength of the AOL. Before dividing AOL, tests showed specimen 3 to be significantly stronger than the other specimens. A longitudinal study would be a useful tool for providing insights into this variation in strength. Having some idea of the donor's occupation and physical hobbies in life may shed some light on variation in ligament strength. It is largely accepted that a lifetime's exposure to abnormal loads at the TMCJ has some influence in development of OA and ligament weakness (13). However, establishing if certain

sports or occupations are risk factors in weakening the AOL would prove beneficial to future prevention of dorsoradial subluxation.

It was noted that force was still recorded when displacing in the dorsoradial plane, even after AOL was divided. It was considered that TMCJ ligaments previously associated with dorsoradial subluxation, such as dorsoradial and IMC ligaments, are still resisting to some degree despite AOL division. Identifying which ligaments are still involved, and their respective influences would provide a complete picture of TMCJ ligaments and their potentially cumulative role in preventing dorsoradial subluxation.

The data presented in this paper provides biomechanical support for the importance of targeting AOL in surgical repair; especially in dorsoradial subluxation of the thumb. The AOL can now be recommended as the major target for repair of dorsoradial subluxation of the thumb at the TMCJ. Furthermore, this biomechanical model and data will provide a platform for future investigations, detailing respective influences of the trapeziometacarpal ligaments on different planes of movement. In time, this will provide a more complete clinical picture of the TMCJ, an area in which treatment of injuries and early onset OA remains unclear.

Acknowledgment

Mr. Iain Campbell and Mrs. Susan Bond, Department of Anatomy, University of Edinburgh- for their help in coordinating and facilitating the study. They went above and beyond to make time for me and were vital in connecting the various aspects of this project.

Mark R. McCann MSc
Department of Anatomy, Edinburgh University Medical School, UK

Philippa A. Rust MD
Hand Surgery Unit, St John's Hospital, Livingston, UK

Robert Wallace PhD
Department of Orthopaedics, University of Edinburgh, UK

References

1. Brunelli GR. Stability of the first carpometacarpal joint. In: Brüser P, Gilbert A, editors. Finger bone and joint injuries. Abingdon: Taylor & Francis; 1999. P. 167-70.
2. Gander B, Wollstein R. Surgical treatment for thumb CMC joint arthritis. *Curr Rheumatol Rev.* 2013; 9(2):113-8.
3. Halilaj E, Rainbow MJ, Moore DC, Laidlaw DH, Weiss AP, Ladd AL, et al. In vivo recruitment patterns in the anterior oblique and dorsoradial ligaments of the first carpometacarpal joint. *J Biomech.* 2015; 48(10):1893-8.

4. D'Agostino P, Kerkhof FD, Shahabpour M, Moermans JP, Stockmans F, Vereecke EE . Comparison of the anatomical dimensions and mechanical properties of the dorsoradial and anterior oblique ligaments of the trapeziometacarpal joint. *J Hand Surg Am.* 2014; 39(6): 1098-107.
5. Bettinger PC, Berger RA. Functional ligamentous anatomy of the trapezium and trapeziometacarpal joint (gross and arthroscopic). *Hand Clin.* 2001; 17(2):151-68.
6. Van Brenk B, Richards RR, Mackay MB, Boynton EL. A biomechanical assessment of ligaments preventing dorsoradial subluxation of the trapeziometacarpal joint. *J Hand Surg Am.* 1998; 23(4):607-11.
7. Colman M, Mass DP, Draganich, LF. Effects of the deep anterior oblique and dorsoradial ligaments on trapeziometacarpal joint stability. *J Hand Surg Am.* 2007; 32(3):310-7.
8. Neumann DA, Bielefeld T. The carpometacarpal joint of the thumb: stability: deformity and therapeutic intervention. *J Orthop Sports Phys Ther.* 2003; 33(7):386-99.
9. Park MJ, Lichtman G, Christian JB, Weintraub J, Chang J, Hentz VR, et al. Surgical treatment of thumb carpometacarpal joint arthritis: a single institution experience from 1995-2005. *Hand (N Y).* 2008; 3(4):304-10
10. Rust PA, Tham SK. Ligament reconstruction of the trapezium-metacarpal joint for early arthritis: a preliminary report. *J Hand Surg Am.* 2011; 36(11):1748-52.
11. Noyes FR, Torvik PJ, Hyde WB, DeLucas JL. Biomechanics of ligament failure. II. An analysis of immobilization, exercise, and reconditioning effects in primates. *J Bone Joint Surg Am.* 1974; 56(7):1406-18.
12. Najima H, Oberlin C, Alnot JY, Cadot B. Anatomical and biomechanical studies of the pathogenesis of trapeziometacarpal degenerative arthritis. *J Hand Surg Br.* 1997; 22(2):183-8.
13. Pellegrini VD Jr, Olcott CW, Hollenberg G. Contact patterns in the trapeziometacarpal joint: the role of the palmar beak ligament. *J Hand Surg Am.* 1993; 18(2):238-44.